CODE: T3100 M4100/3

ID NOS: H334875 A15308

DIAGNOSIS: HEART - FIBRINOUS PERICARDITIS.

CLINCIAL HISTORY: F/71. This pathological change, unsuspected during life, was found post mortem in an elderly woman who died of carcinoma of the lung with superimposed pulmonary abscess (see specimen T2800 M8013/9). The neoplasm had involved the parietal pericardium.

MACROSCOPIC: The epicardium overlying the ventricular wall is partly covered by a pale shaggy network of fibrin. Adhesions between the visceral pericardium and parietal pericardium were readily broken down at autopsy.
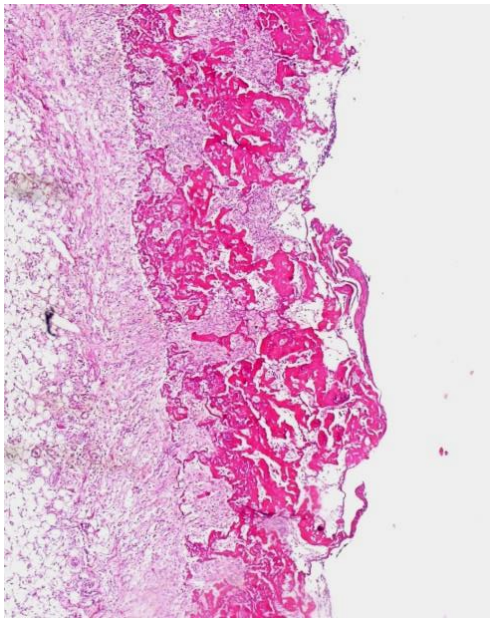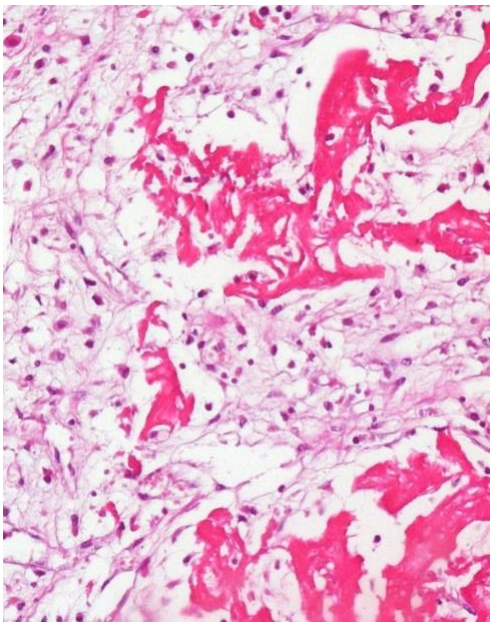
MICROSCOPIC: A thick layer of fibrin has been deposited on the pericardium. The latter shows some congestion and a mild cellular inflammatory cell infiltrate. Pale areas extending into the deeper layers of fibrin from the original surface are foci of organisation.