CODE: T0400 M3211

ID NOS: None

DIAGNOSIS: BREAST – SILICONE IMPLANT

CLINICAL HISTORY: F/ Age unknown. The patient had previous silicone implant in her breast. This was removed because of persistent pain.

MACROSCOPIC: The specimen shows the smooth pale implant with part of the irregular fibrous capsule which had developed around the prosthesis.

MICROSCOPIC: The section of the capsule shows fibrosis with irregular clear spaces and a foreign body inflammatory reaction. Some of the multinucleate foreign body giant cells contain refractile silicone material, indicating there had been some leakage from the implant.
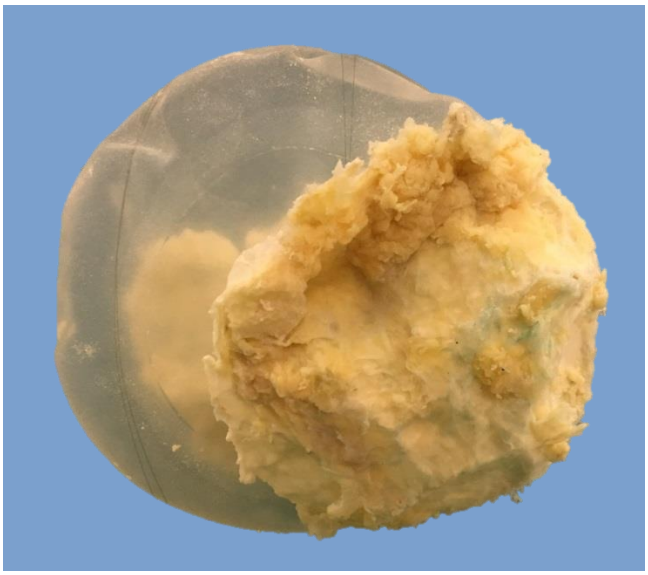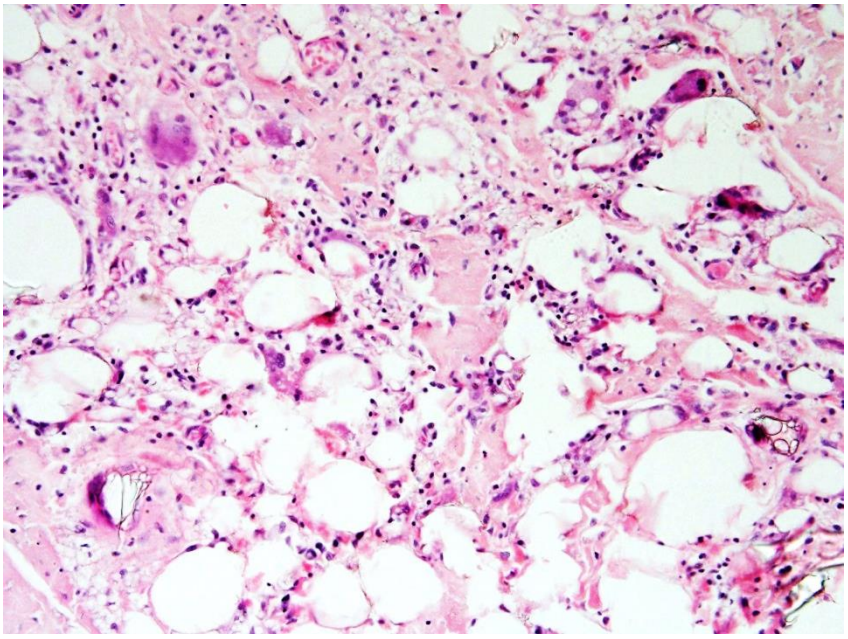
.