CODE: T3100 M8006

ID NOS: H364637 A16165

DIAGNOSIS: HEART – PERICARDIAL METASTASES FROM PLEURAL MESOTHELIOMA

CLINICAL HISTORY: M/65. Presenting symptoms were increasing dyspnoea and cardiac failure. Echo-cardiography demonstrated a pericardial effusion for which a window was formed with no significant benefit. He died following an epileptic fit.

MACROSCOPIC: The heart shows thickening of the pericardium by pale tissue 4-5mm in thickness. Nodular thickening is also present especially on the superior aspect of the specimen. Post mortem showed the primary tumour was a pleural mesothelioma.
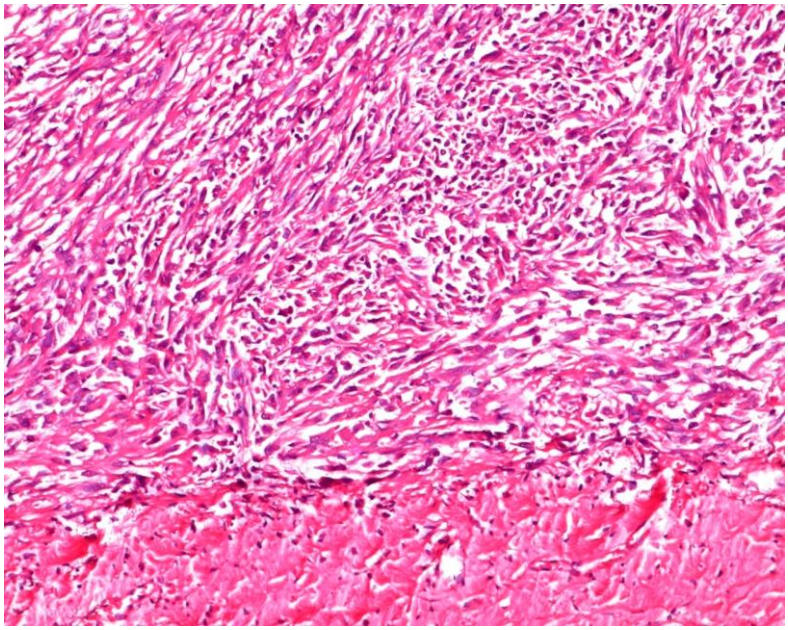
MICROSCOPIC: Section shows the tumour is composed predominantly of plump spindle cells, and is consistent with a sarcomatoid mesothelioma.