CODE: T3200 E1743

ID NOS: HSM7236 A17467

DIAGNOSIS: HEART – POST MORTEM EFFECTS OF CLOSTRIDIUM PERFRINGENS.

CLINICAL HISTORY: M/37. Bilateral nephrectomies for chronic renal failure and hypertension. Small bowel ileus with septicaemia. Clostridium perfringens was grown on blood cultures the day before death and also from post mortem tissue.

MACROSCOPIC: Cross section of both ventricles of the heart showing marked left ventricular hypertrophy and numerous small holes throughout the myocardium.
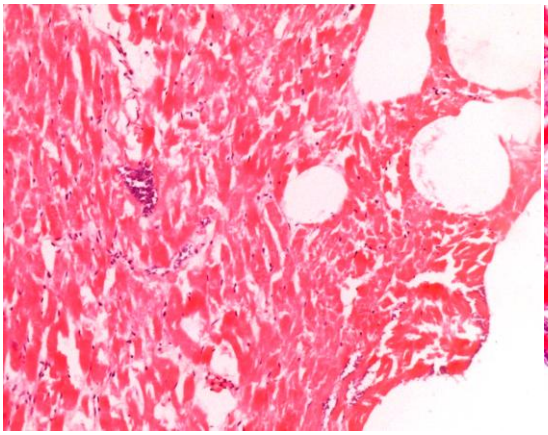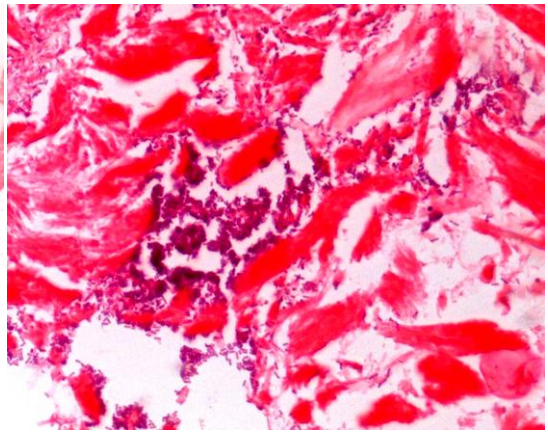
MICROSCOPIC: Sections show holes in the myocardium with collections of rod shaped bacilli (gram positive) related to the holes and throughout the myocardium. There is no cellular reaction indicating that the changes probably occurred post mortem.