CODE: T3200 F9307/1

ID NOS: HCIV2245 A14517

DIAGNOSIS: HEART – ASPERGILLOSIS.

CLINICAL HISTORY: M/34 This man had severe chronic renal failure and received a renal transplant. He died two months later from generalised aspergillosis resulting from immuno suppression.

MACROSCOPIC: Cross section of the myocardium shows small (1-2mm) pale foci resembling military tubercles, and slightly larger lesions bulging the endocardium. Autopsy also showed asperigillosis of the lungs and brain.
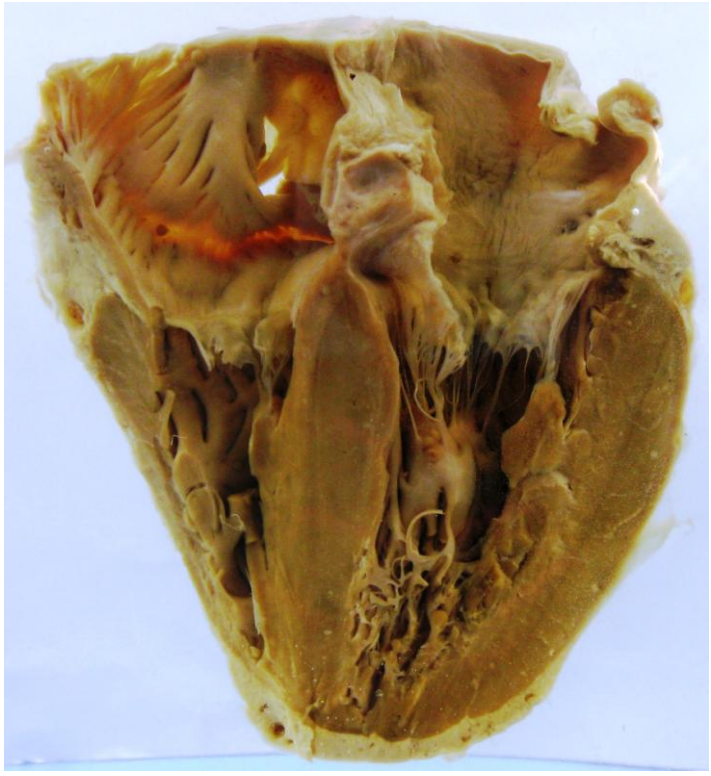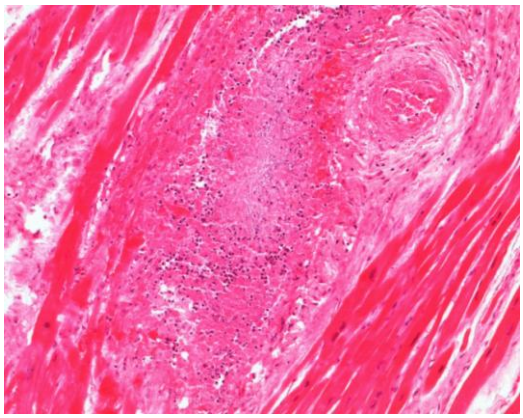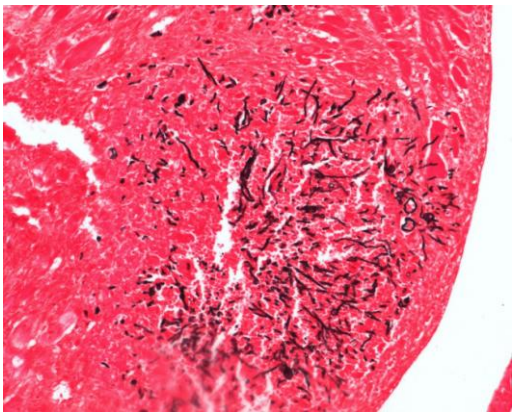
MICROSCOPIC: Sections show the pale lesions are necrotic foci often associated with a thrombosed blood vessel (left). Although fungal hyphae can be seen with H&E stain, they are far more obvious with a methenamine silver stain (right).