CODE: T3200 M5513

ID NOS: HX67417 A17915

DIAGNOSIS: HEART - AMYLOIDOSIS.

CLINICAL HISTORY: M/73. The patient had a long history of chronic obstructive airways disease and ischaemic heart disease, with recent anorexia and weight loss. Small bowel biopsies showed amyloidosis. The heart weighed 480g at autopsy.

MICROSCOPIC: Specimen consists of two transverse sections of heart through the ventricles. The myocardium appears firm. The lower section shows red staining with Congo red indicative of widespread amyloid deposition.

MACROSCOPIC: Scattered pale areas throughout the myocardium show degenerative changes in the muscle fibres with deposition of eosinophilic material (special stains for amyloid were positive).
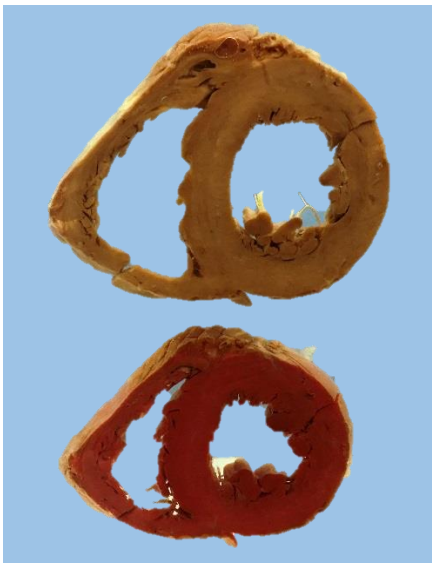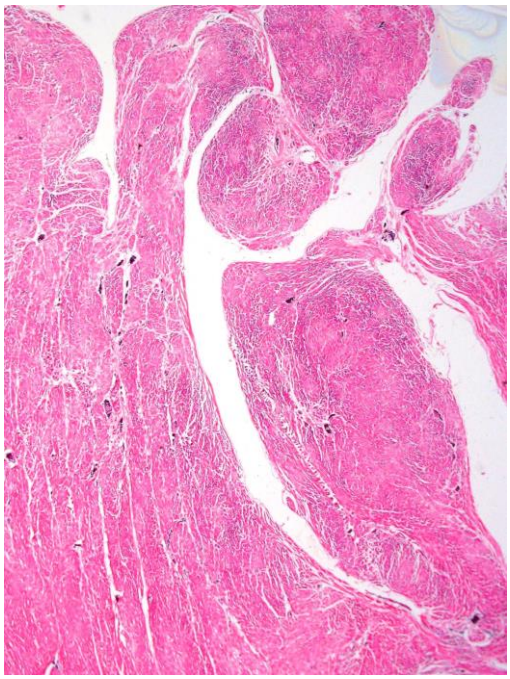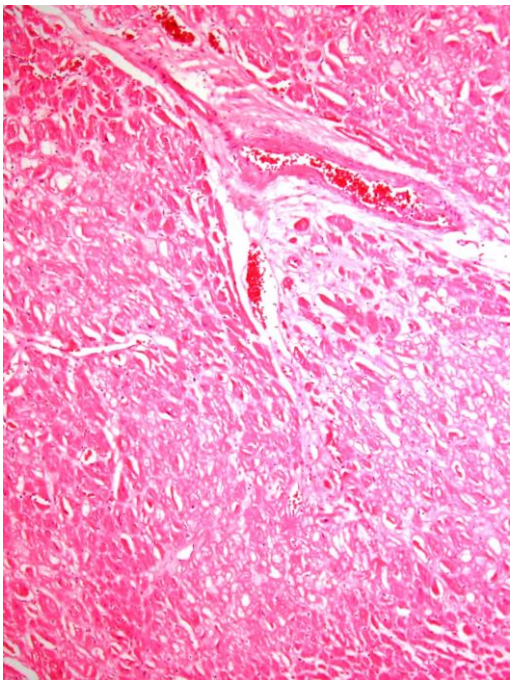
COMMENT: See also specimens: T0700 M5515 (spleen) & T6700 M5513 (colon)