CODE: T3301 M5472/7

ID NOS: 421997 A7582

DIAGNOSIS: HEART - MYOCARDIAL INFARCTION.

CLINICAL HISTORY: M/46. There was a past history of hypertension for which lumbar sympathectomy had been performed. More recently, the patient had developed increasing angina of effort with a final episode of severe and persistent precordial pain a week before death.

MACROSCOPIC: There is pallor and thinning of the anterior portion of the left ventricular wall and interventricular septum. Dark mural thrombus is adherent to this infracted area. The rest of the wall of the left ventricle is thickened. On the reverse side, a serpiginous translucent zone surrounding the opaque infarct represents formed fibrous tissue.
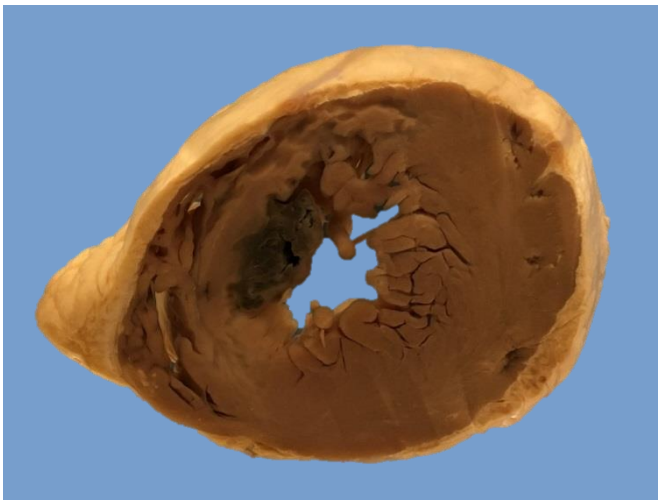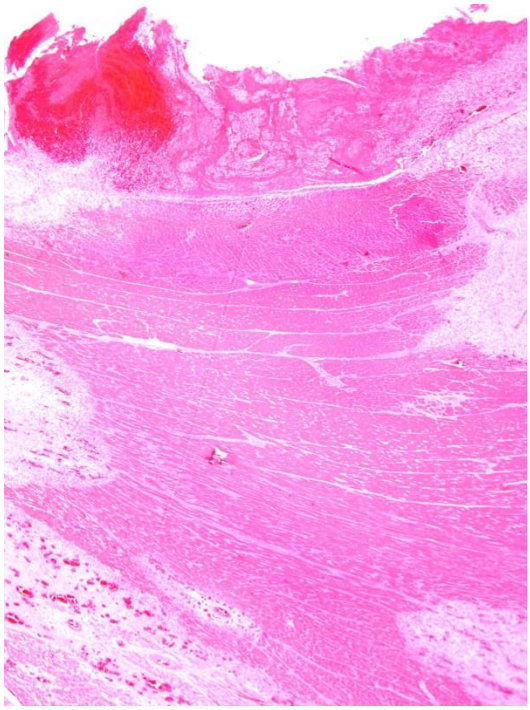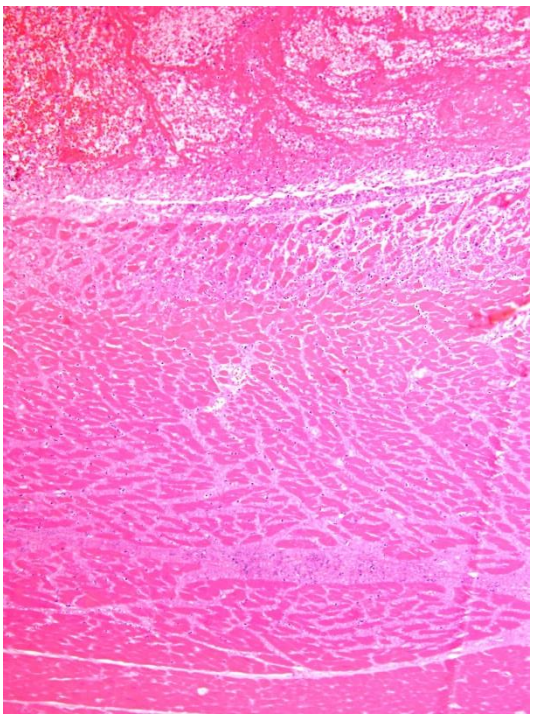
MICROSCOPIC: Fibrin thrombus overlies the necrotic area of recent infarct, and the presence of rather pale cellular fibrous tissue around the infarct indicates a previous ischaemic episode (left image). The necrotic myocardium is infiltrated by neutrophils (right image).