CODE: T3500 M4497/3

ID NOS: 14240, A6083

DIAGNOSIS: CHRONIC RHEUMATIC HEART DISEASE,
MITRAL STENOSIS

CLINICAL HISTORY: M/59. The patient had no knowledge of previous rheumatic fever. His admission to hospital was precipitated by cardiac failure of rapidly increasing severity. Mitral stenosis had been detected thirteen years before and there had been some intervening episodes of cardiac failure with auricular fibrillation.

MACROSCOPIC: The cusps of the mitral valve are thickened and rigid, with craggy deposits of calcium. These changes have reduced the aperture of the valve to a thin buttonhole-like slit. The remaining valves are normal and on the reverse, right ventricular hypertrophy is obvious.
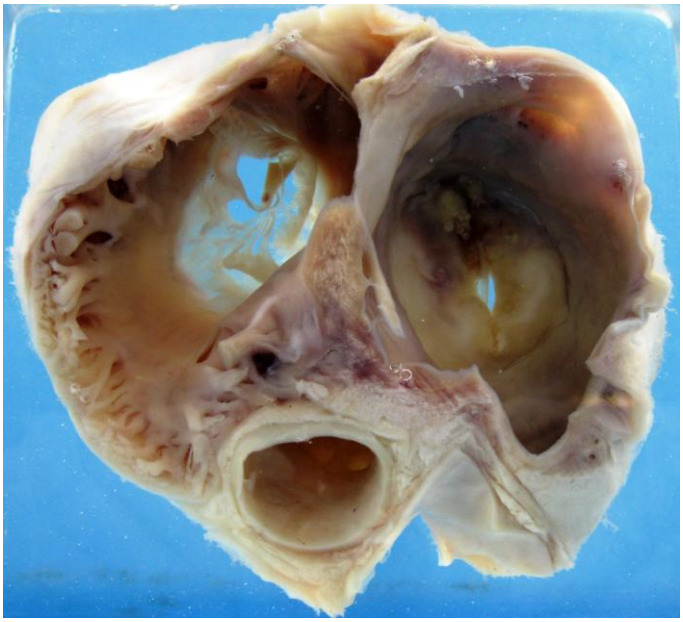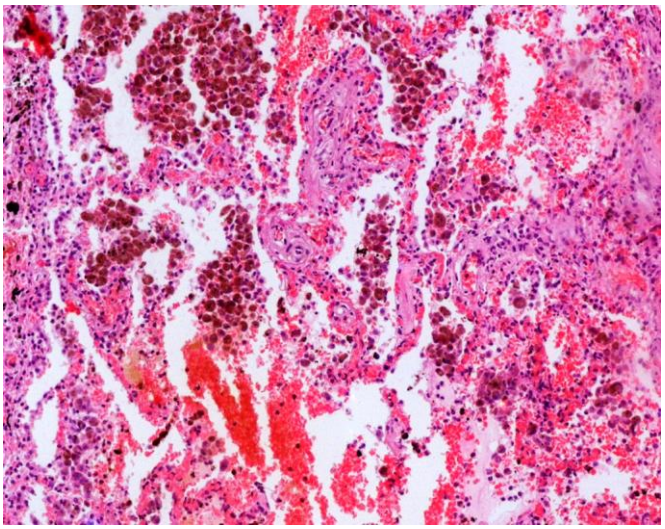
MICROSCOPIC: The lung shows the typical changes of long-standing chronic venous congestion with thickened alveolar walls and densely packed aggregations of haemosiderin-containing macrophages, the so called “heart-failure” cells. There is also some recent intra-alveolar haemorrhage.