CODE: T4200 M3442/7

ID NOS: HX18037 21079

DIAGNOSIS: AHTEROSCLEROTIC ANEURYSM OF AORTA.

CLINICAL HISTORY: M/69. Whilst in hospital for treatment of cardiac failure, a tender pulsating mass was palpated in the abdomen. An aneurysm of the aorta distal to the renal arteries was surgically removed and a teflon graft inserted. Four years earlier a small aneurysm was noted during an operation for peptic ulcer.
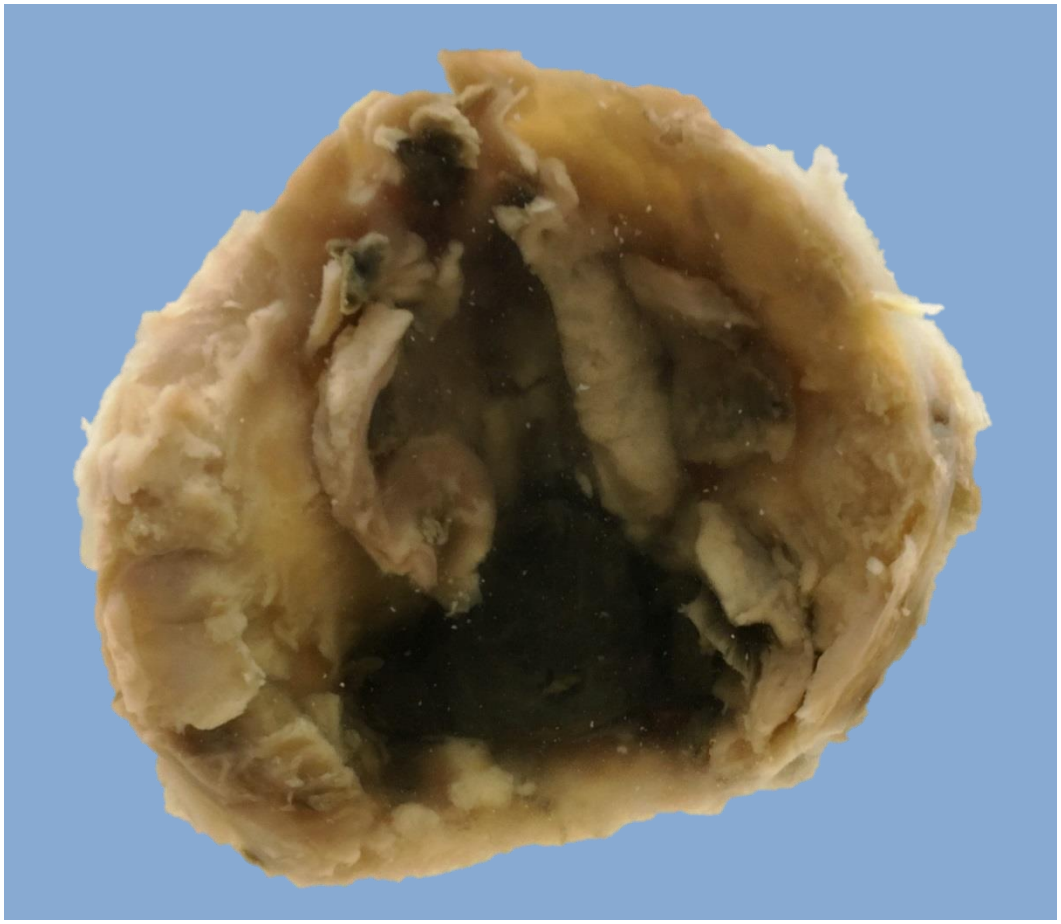
MACROSCOPIC: The surgical specimen is the aneurysm which was resected from the lower end of the abdominal aorta. The wall can be seen to be very atherosclerotic and there is both old and recent mural thrombus superimposed.