CODE: T42000 M35100

ID NOS: HX226728 161855

DIAGNOSIS: THROMBUS FROM AORTIC ANEURYSM

CLINICAL HISTORY: Thrombus removed from saccular abdominal aneurysm at time of repair and graft.

MACROSCOPIC: The specimen consists of portion of a tripolar thrombus. The cut surface shows a laminated thrombus with a lumen along one edge.
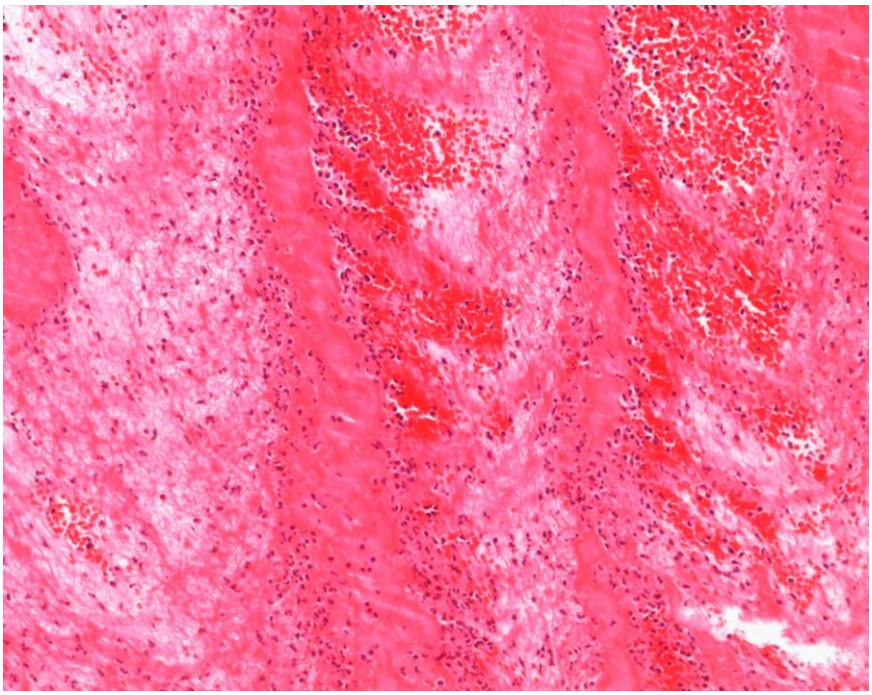
MICROSCOPIC: Sections show pale streaks of massed platelets and fibrin bordered by neutrophils, alternating with dark areas of massed erythrocytes and leucocytes.