CODE: T4512 M5211

ID NOS; None - donated specimen

DIAGNOSIS: CAROTID ARTERIES – ATHEROSCLEROTIC PLAQUES

CLINICAL HISTORY: No history is available, apart from the fact that these atherosclerotic plaques were removed from the left common carotid artery and the left external carotid artery. However the symptoms of carotid stenosis may include amaurosis fugax (temporary loss of vision in the eye), a transient ischaemic episode or a complete stroke.

MACROSCOPIC: This endarterectomy surgical specimen consists of two atherosclerotic plaques. The intimal surfaces of both are very irregular. The upper specimen contains yellowish plaques of atheroma. The lower specimen shows a plaque which appears to have narrowed the lumen of the artery and shows evidence of haemorrhage.
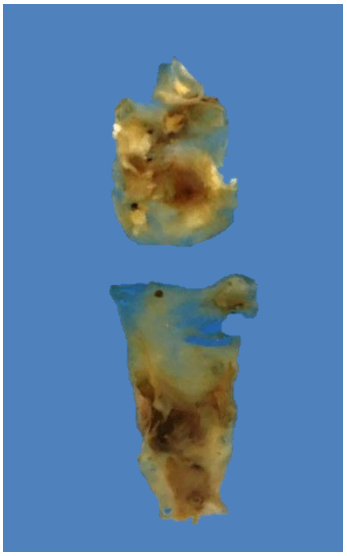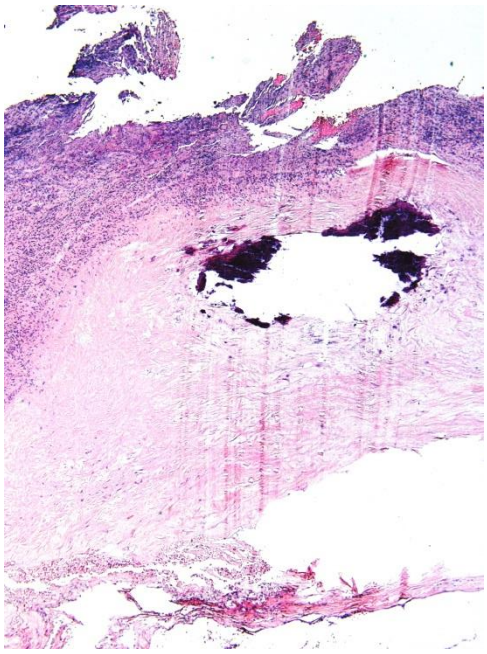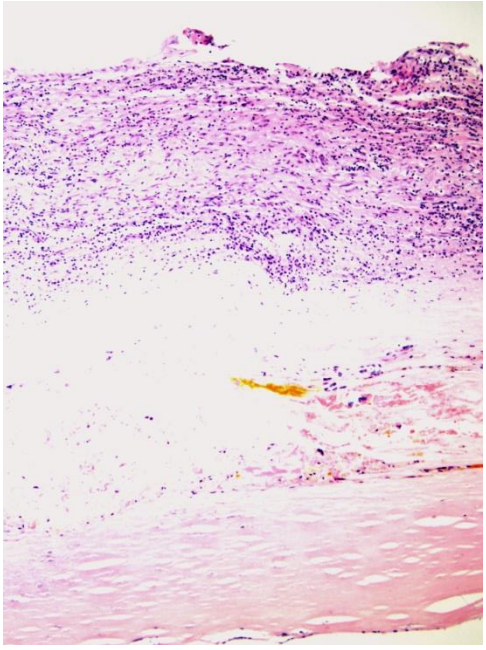
MICROSCOPIC: The plaque has deposition of fatty material with dark staining calcification, an inflammatory reaction and ulceration of the intimal surface (left image). The yellow pigment indicates previous haemorrhage in the plaque (right image).