CODE: T4800 M3460/1

ID NOS; HB112741 42596

DIAGNOSIS: THROMBOSIS IN A SAPHENOUS VARIX

CLINICAL HISTORY: F/81. This elderly woman received an injury to the inner aspect of her thigh three months before she presented to outpatients. Following this injury a soft swelling developed in the region which became firm and painful.

MACROSCOPIC: This surgical specimen consists of a greatly dilated saphenous vein filled with blood clot, the centre of which is paler than the periphery.
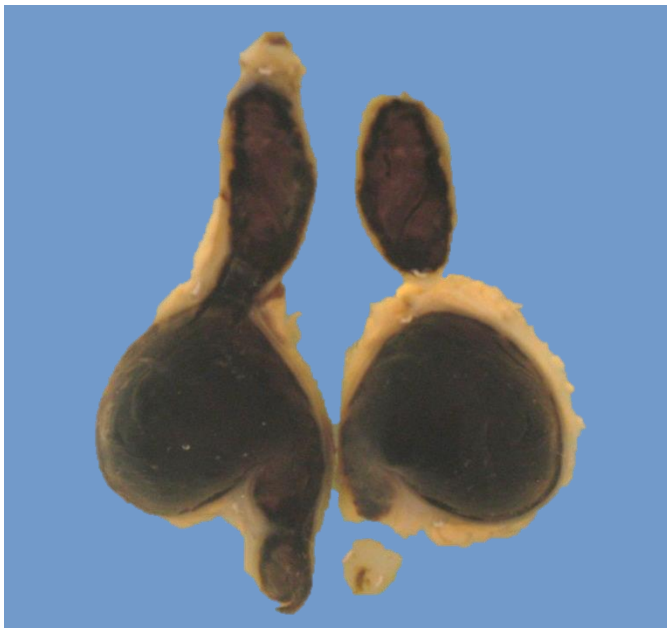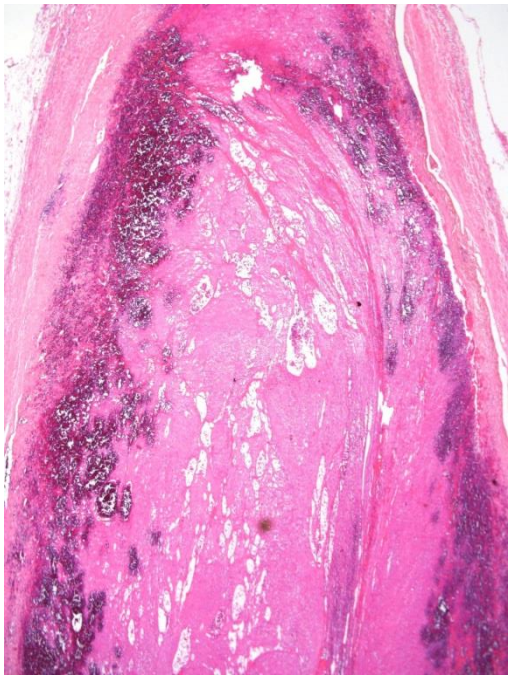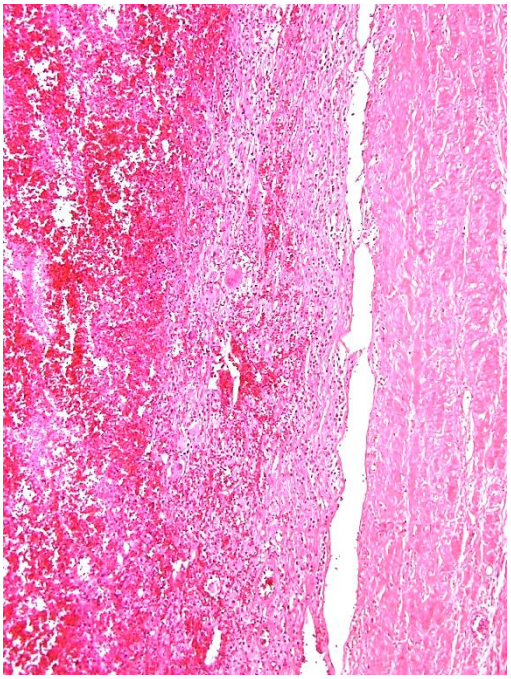
MICROSCOPIC: The thrombosis is undergoing organisation and some new thin walled blood vessels have developed.