CODE: T9600 M7233/1

ID NOS: 12509

DIAGNOSIS: THYROID – NODULAR COLLOID GOITRE

CLINICAL HISTORY: F/59. A slow increase and nodularity of the thyroid gland led to thyroidectomy. There were no other symptoms.

MACROSCOPIC: Four nodules of different size are present in this lobe of the thyroid. The larger upper nodule shows haemorrhagic areas, fibrosis and a few small pale foci of calcification. The nodule at the lower pole has undergone partial cystic degeneration.
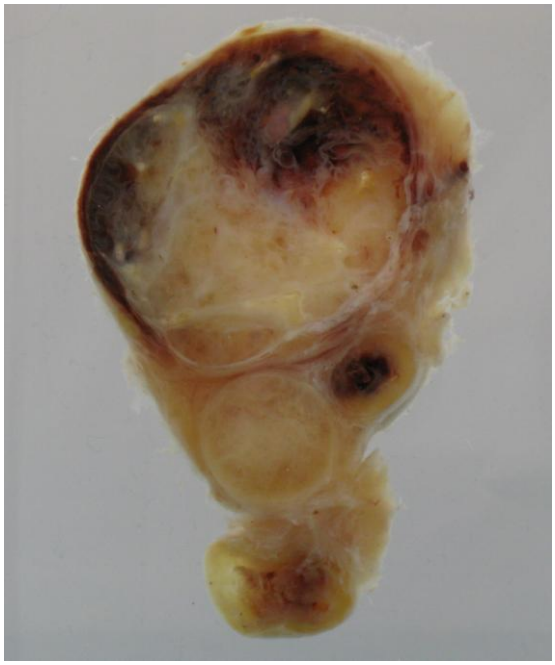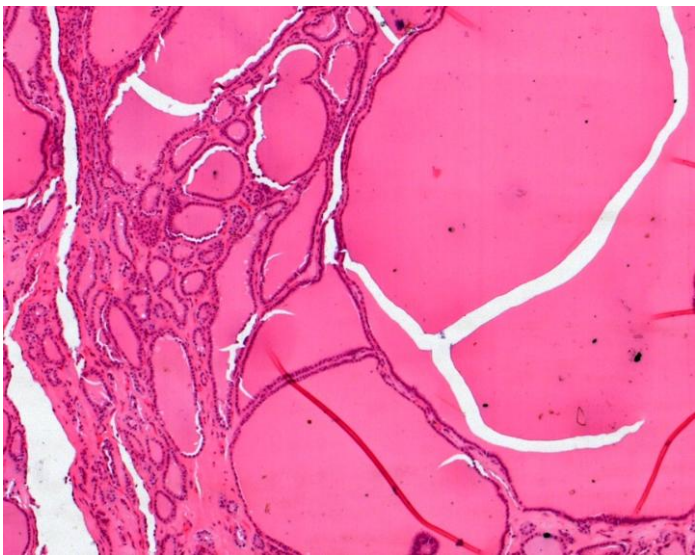
MICROSCOPIC: Many of the thyroid follicles are markedly distended with colloid and are lined by flattened epithelium.