**CODE:** T9600 M7233/2

**ID NOS:** 2/7153 8738

**DIAGNOSIS:** THYROID – NODULAR COLLOID GOITRE

**CLINICAL HISTORY:** M/33. The patient noticed the sudden appearance of a lump in his neck. There were no symptoms of hyperthyroidism and a diagnosis was made of haemorrhage into a thyroid nodule. Hemi-thyroidectomy was performed.

**MACROSCOPIC:** The lobe of thyroid tissue has been bisected and laid open. The cut surface shows several nodules of varying appearances and most contain colloid. One nodule contains dark brown material resulting from previous haemorrhage. On the reverse the surface of the gland is coarsely nodular.
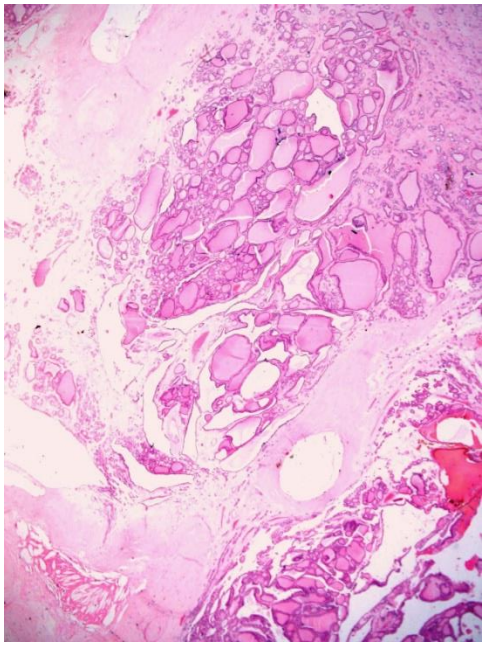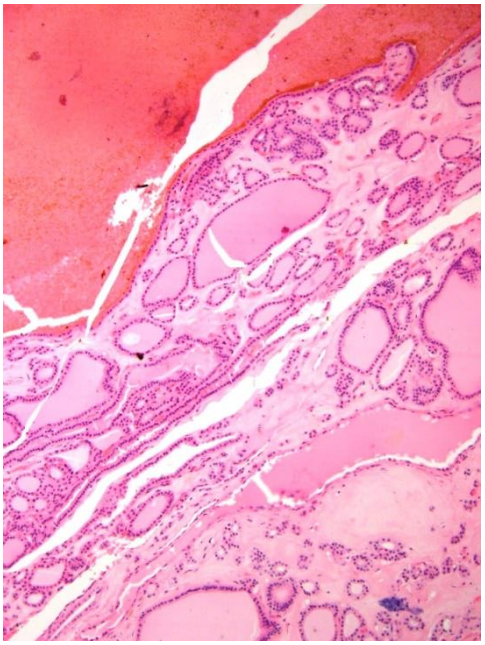
**MICROSCOPIC:** The left image shows nodules of thyroid follicles containing colloid with surrounding fibrosis. The right image show haemorrhage into a cyst.