CODE: T9700 M8140/1

ID NOS: HX259329 22065

DIAGNOSIS: PARATHYROID – ADENOMA

CLINICAL HISTORY: M/50. The patient complained of increasing attacks of renal colic, and on investigation was found to have bilateral ureteric calculi and hydronephrosis. His serum calcium was elevated with a normal phosphate, and despite the absence of radiological signs, he was thought to have hyperparathyroidism. His neck was explored surgically and an enlarged right inferior parathyroid gland was found. Subsequently his serum calcium returned to normal, the hydronephrosis diminished and he died from unrelated causes 10 years later.

MACROSCOPIC: The nodule has been bisected and has a uniform pale cut surface. It originally measured up to 2.5cm in diameter.
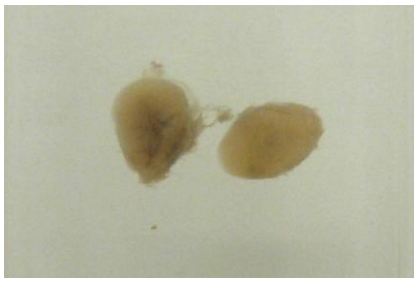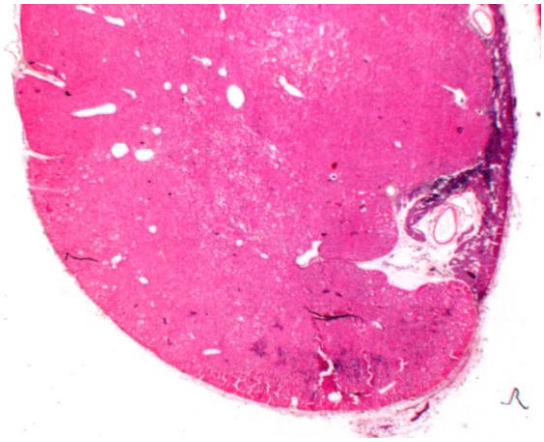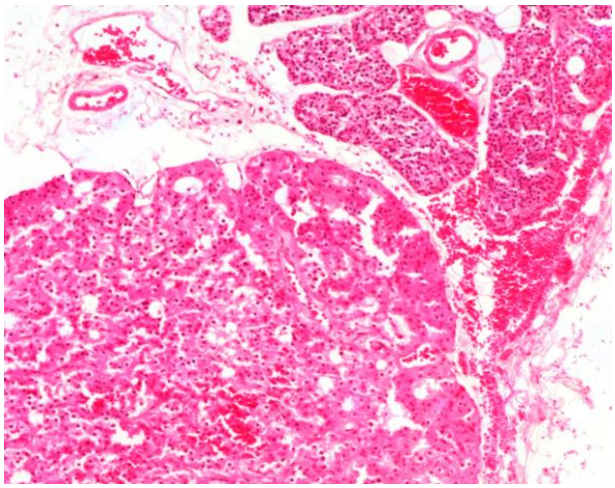
MICROSCOPIC: The tumour consists mainly of eosinophilic cells, which can be compared with the smaller chief cells in the adjacent normal parathyroid tissue (lower image).