CODE: TXX00 M8073

ID NOS: H462572 160438

DIAGNOSIS: ORBIT OF EYE – SQUAMOUS CELL CARCINOMA

CLINICAL HISTORY: F/77. The patient presented with an eight week history of rapidly increasing swelling of the right eyelids with ptosis. A squamous cell carcinoma had been removed from the right temple five years earlier.

MACROSCOPIC: The specimen consists of the right eye and orbit, and including upper and lower eyelids, supra-orbital skin and a portion of the right frontal bone (left image). There is a pale tumour mass 20mm across between the eyeball and the bone, eroding through the bone and lifting the dura (right image).
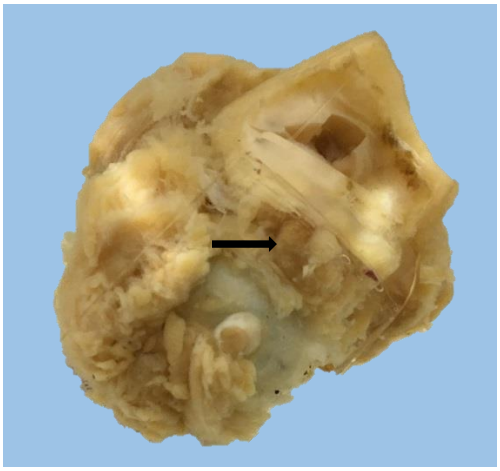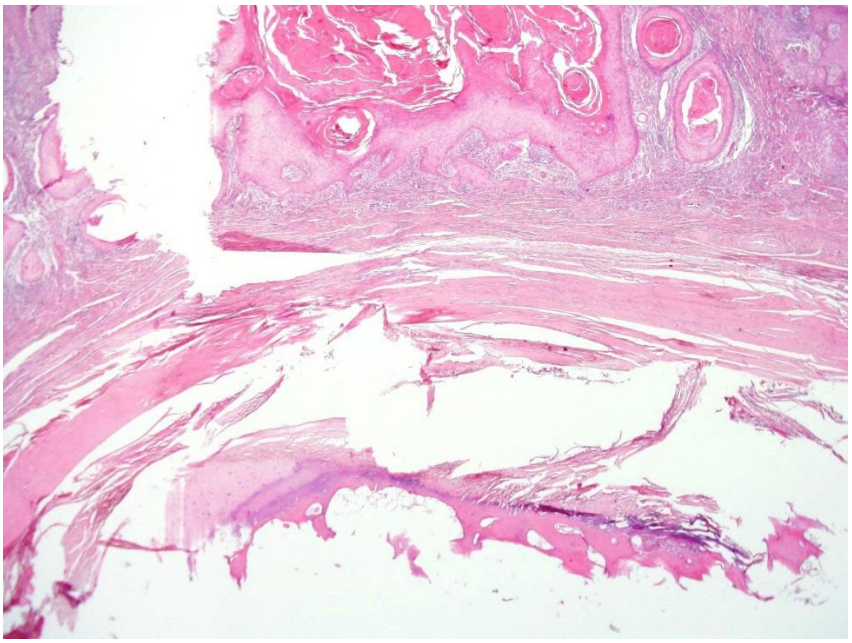
MICROSCOPIC: Sections of the tumour show an infiltrating moderately well differentiated squamous cell carcinoma, with bone in the lower half of the image.