CODE: T8700 M8496/1

ID NOS: H305158 90988

DIAGNOSIS: KRUCKENBERG TUMOURS OF THE OVARIES

CLINICAL HISTORY: F/38. At the age of 34, this patient underwent gastrectomy for carcinoma of the stomach – linitus plastica type. She received chemotherapy and remained well for three years when an abdominal mass developed. Both ovaries were found to be enlarged and were surgically removed. Recurrences were being treated a year later.

MACROSCOPIC: Both ovaries are greatly enlarged, and have been bisected to show solid yellowish tissue. A small cyst is noted at the back of one ovary, and there is a segment of fallopian tube present.
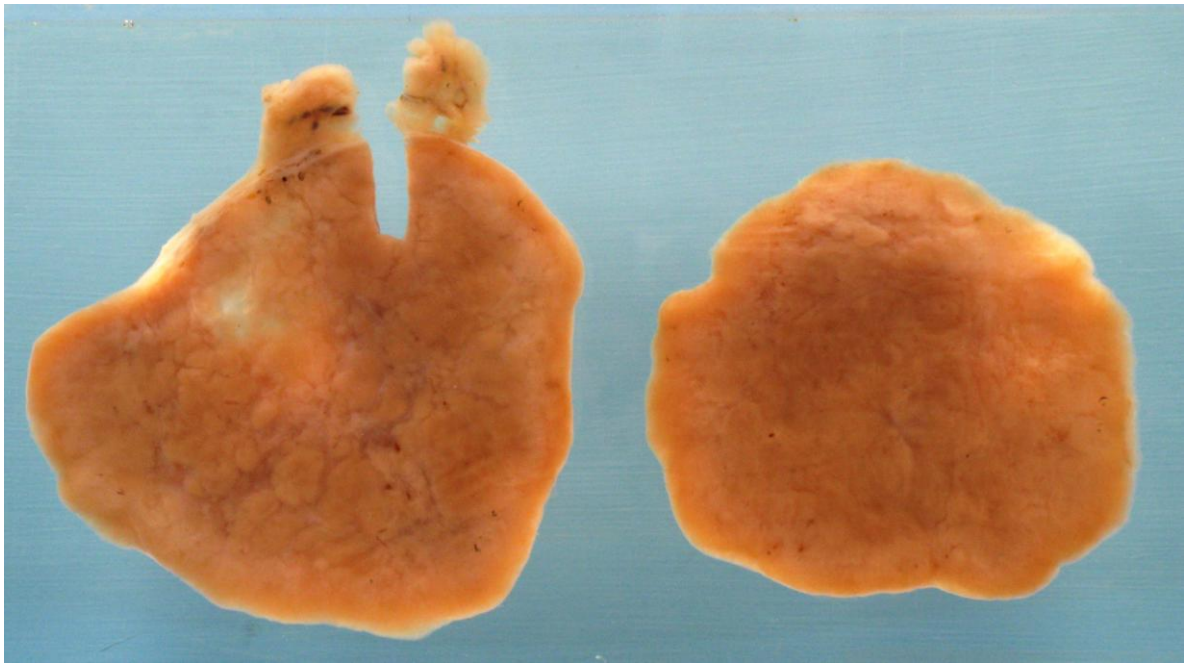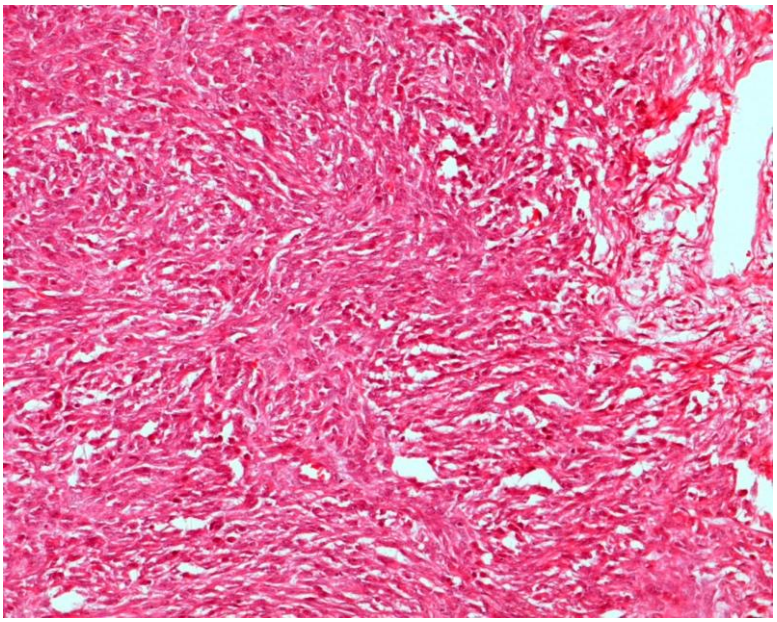
MICROSCOPIC: The predominant cell is spindle shaped. There are occasional epithelial cells, some with a large vacuole giving a signet ring morphology.