**CODE:** T5300 M8073/4

**ID NOS:** HX283991 A15297

**DIAGNOSIS:** SQUAMOUS CARCINOMA OF BASE OF TONGUE.

**CLINICAL HISTORY:** M/57. Nine months before death, this patient presented with a six week history of sore throat and dysphagia. Examination showed an ulcer on the posterior third of the tongue and a biopsy showed the lesion to be a squamous carcinoma. Following a course of radiotherapy, the ulcer appeared to heal but later recurred. It did not respond to chemotherapy and death was finally due to massive haemorrhage.

**MACROSCOPIC:** A deep penetrating ulcer involves the root of the tongue and lies just anterior to the epiglottis. The pale tissue surrounding the ulcer is infiltrating carcinoma.
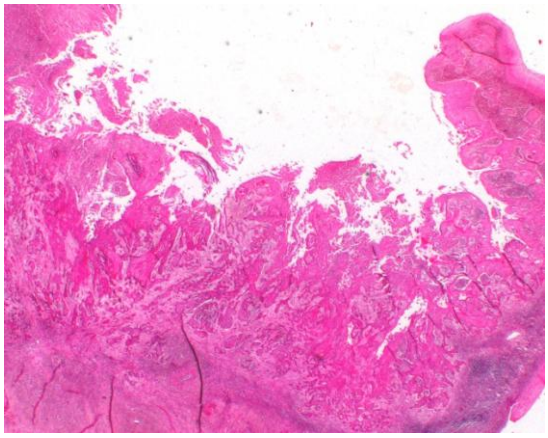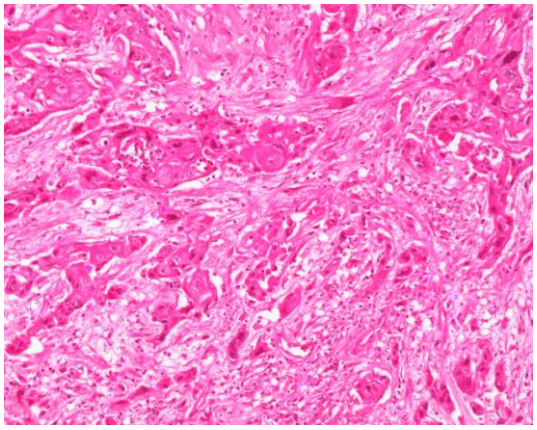
**MICROSCPIC:** The left image shows an ulcerated moderately differentiated squamous carcinoma. The right image show the tumour is infiltrating the surrounding connective tissue.