CODE: T5600 M4851/3 M8173

ID NOS: HX26473 A15474

DIAGNOSIS: LIVER - ALCOHOLIC CIRRHOSIS + HEPATOCELLULAR CARCINOMA.

CLINICAL HISTORY: M/56. The patient was diagnosed with alcoholic cirrhosis four years before death. During the final hospital admission, oedema and ascites were prominent features and death finally resulted from hepatic coma.

MACROSCOPIC: The capsular surface of the liver (left) is nodular, and the cut surface of the right lobe shows destruction of the parenchyma by a pale diffusely infiltrating tumour. In the centre of the specimen there is a large portal vein radicle containing red thrombus.
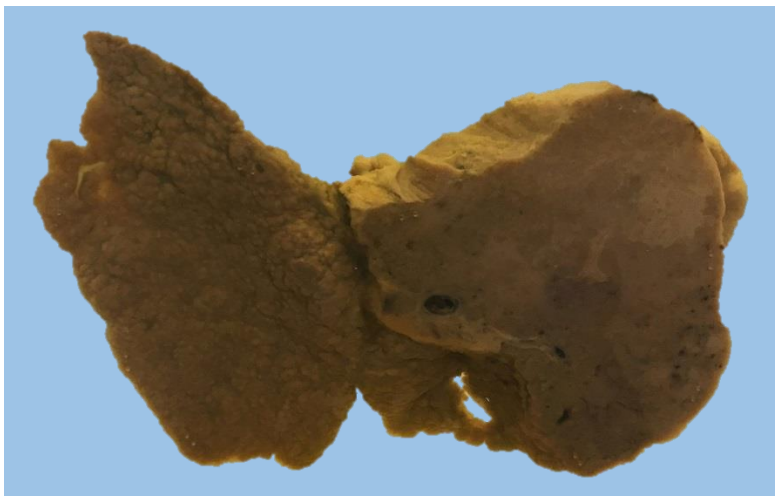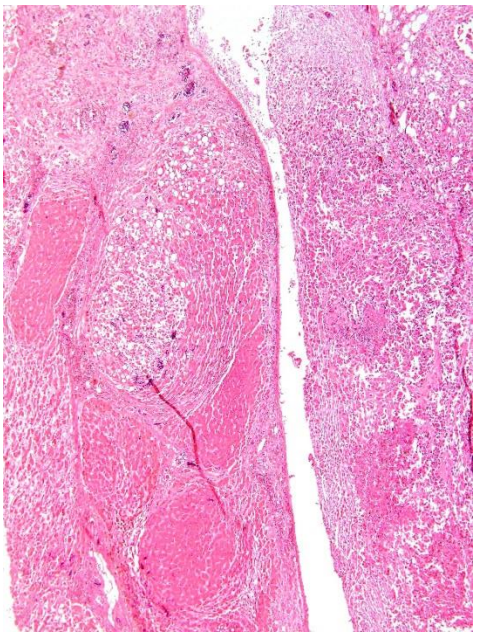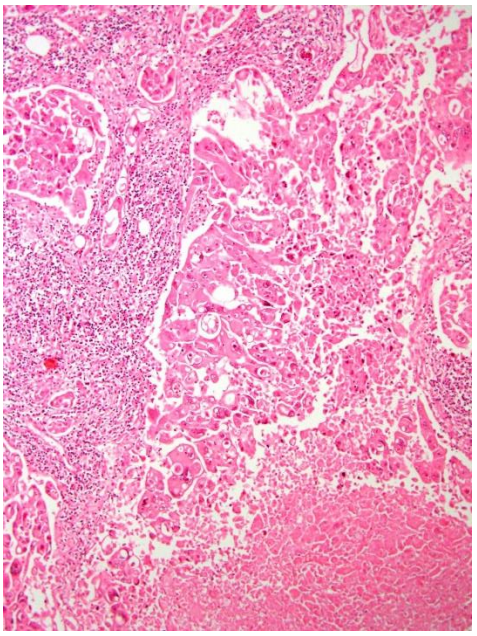
MICROSCOPIC: There is a micronodular cirrhosis in which there are multiple foci of hepatocellular carcinoma (left image). The tumour is pleomorphic with necrosis and associated with a patchy inflammatory cell infiltrate (right image).