CODE: T5700 M5524

ID NOS: Unknown

DIAGNOSIS: GALL BLADDER - CHOLESTEROLOSIS

CLINICAL HISTORY: Not available.

MACROSCOPIC: This donated specimen shows a gall bladder with numerous flecks on the mucosal surface which is typical of cholesterolosis. This is usually associated with cholesterol stones.
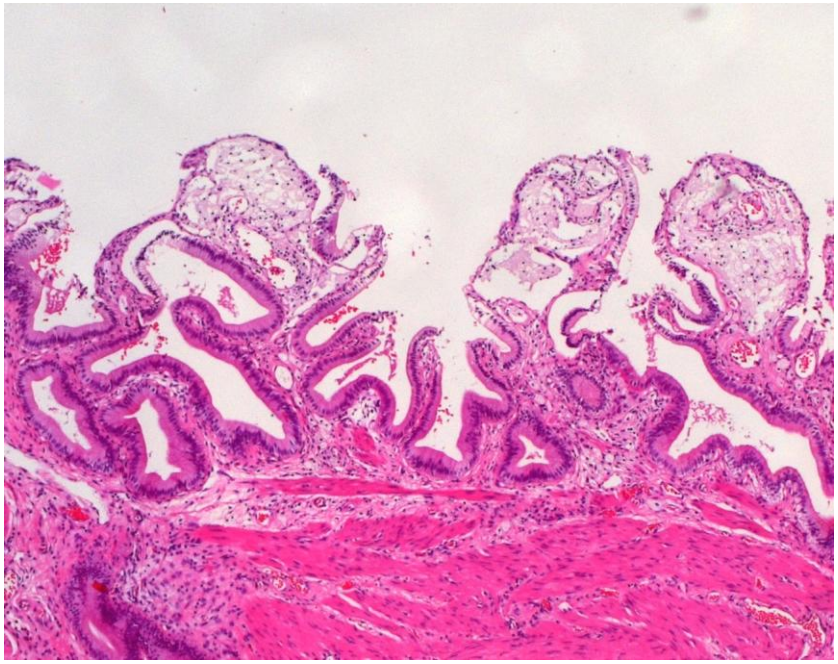
MICROSCOPIC: The mucosal folds contain prominent pale foamy histiocytes, typical of cholesterolosis.