CODE: T5700 M5524/2

ID NOS: 195459

DIAGNOSIS: GALL BLADDER - CHOLESTEROLOSIS

CLINICAL HISTORY: F/38. The patient had recurrent episodes of biliary colic and a laparoscopic cholecystectomy was performed. A single stone was present in the gall bladder.

MACROSCOPIC: The entire mucosal surface of the gall bladder shows diffuse small yellowish flecks typical of cholesterolosis.
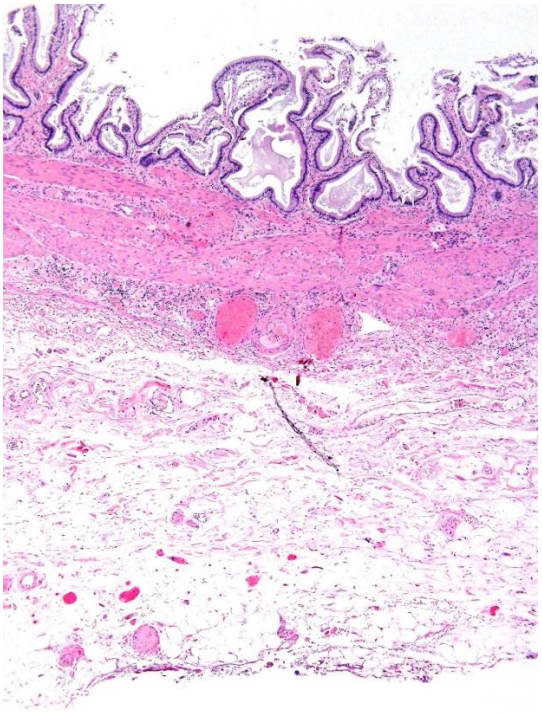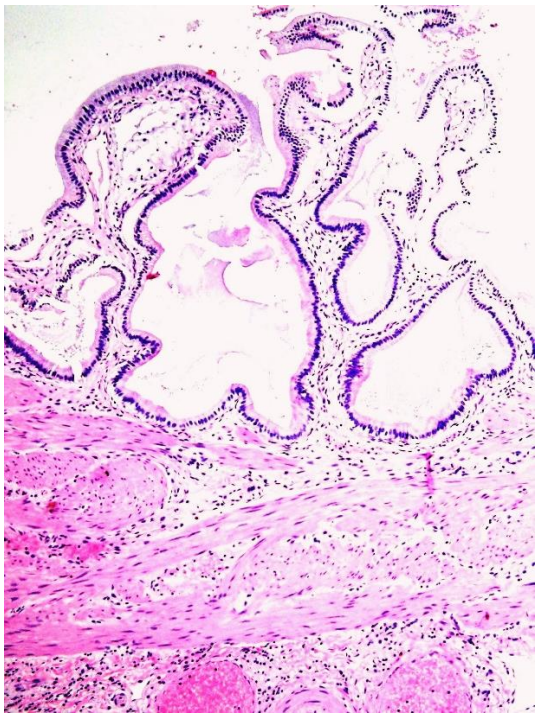
MICROSCOPIC: There is fibromuscular hyperplasia and a mild chronic inflammatory cell infiltrate consistent with chronic cholecystitis (left image). The mucosal folds contain aggregates of pale foamy histiocytes, typical of cholesterolosis (right image).