CODE: T5700 M8013/2

ID NOS: 10683

DIAGNOSIS: GALL BLADDER – ADENOCARCINOMA

CLINICAL HISTORY: F/66 . The patient had a history of nausea with occasional vomiting, anorexia and weight loss for several weeks. Physical examination revealed jaundice and a hard irregular mass was felt in the right hypochondrium. Laparotomy showed a distended gall bladder containing white bile and stones.

MACROSCOPIC: When received, the gall bladder was distended with clear mucus and multiple mixed stones. The mucosa is congested, haemorrhagic and at places finely nodular. About 2cm from the fundus, the wall is constricted by a pale, neoplastic mass about 2cm diameter. The tumour is invading through to the serosal surface. The cystic duct is dilated and its valves appear prominent.
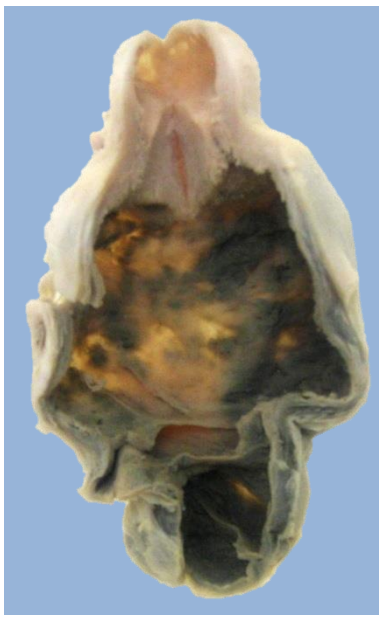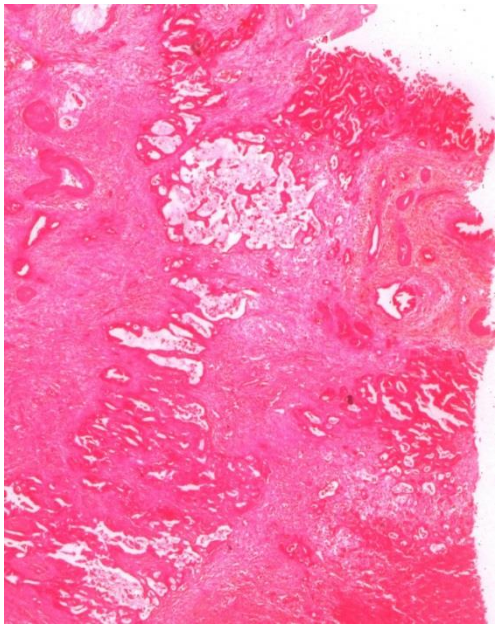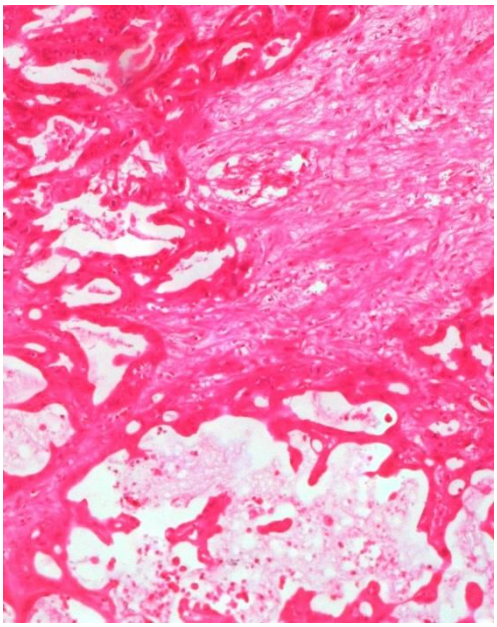
MICROSCOPIC: Sections show the gall bladder wall is infiltrated by adenocarcinoma, which has prominent mucus production in some areas.