**CODE:** T58000 M81403

**ID NOS:** HX292931 151581

**DIAGNOSIS:** CHOLANGIOCARCINOMA

**CLINICAL HISTORY:** M/70. The patient had painless jaundice for one week. A CT scan showed obstruction of the left hepatic duct. The left lobe of the liver and adjacent portion of the right lobe were resected, together with hepatic ducts and the gall bladder.

**MACROSCOPIC:** Specimen consists of portion of both lobes of the liver with attached hepatic ducts and gall bladder. In the region of the porta hepatis there is a tumour within the left hepatic duct extending into the common hepatic duct. The ulcerated polypoid tumour can be seen in the opened dilated common hepatic bile duct.
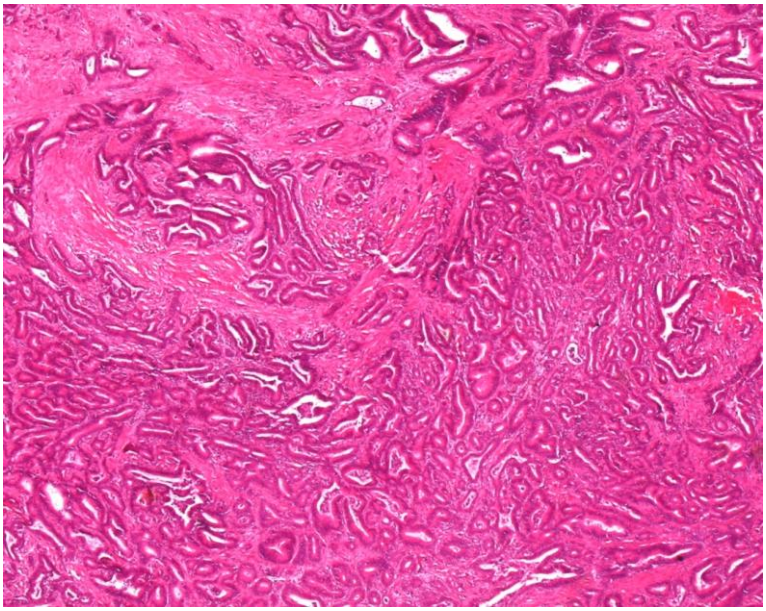
**MICROSCOPIC:** Sections show moderately differentiated well adenocarcinoma with prominent fibrous stroma.