CODE: T6300 M4003/5

ID NOS: Donated specimen 55

DIAGNOSIS: STOMACH - ULCERS

CLINICAL HISTORY: F/58. The patient had a long history of dyspepsia with upper abdominal discomfort. She also had episodes of melaena associated with anaemia. Gastrectomy was performed because of massive bleeding.

MACROSCOPIC: The specimen of stomach shows a deep ulcer 8mm in diameter near the distal end, with a blood vessel visible at the base. There is also a shallow ulcer in the mid stomach centred on the lessor curve.

MICROSCOPIC: Sections show mucosal ulceration with organising granulation tissue at the base covered by inflammatory exudate (left image), The adjacent mucosa show gastritis. Blood vessels in the floor of the ulcer show fibrinoid change (right image).
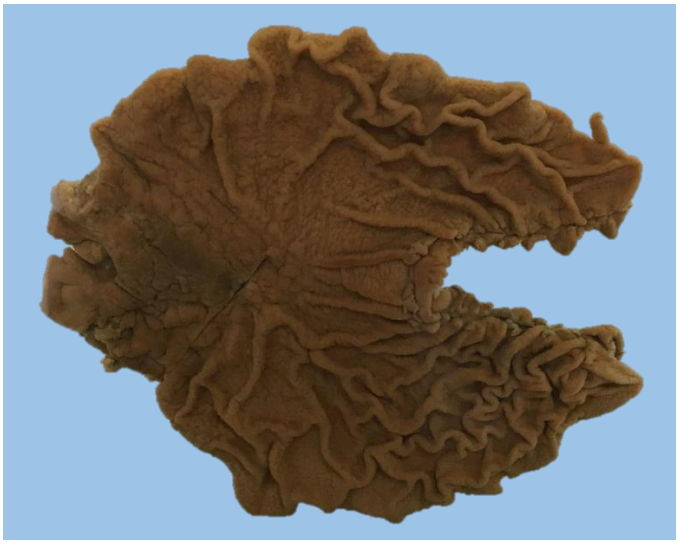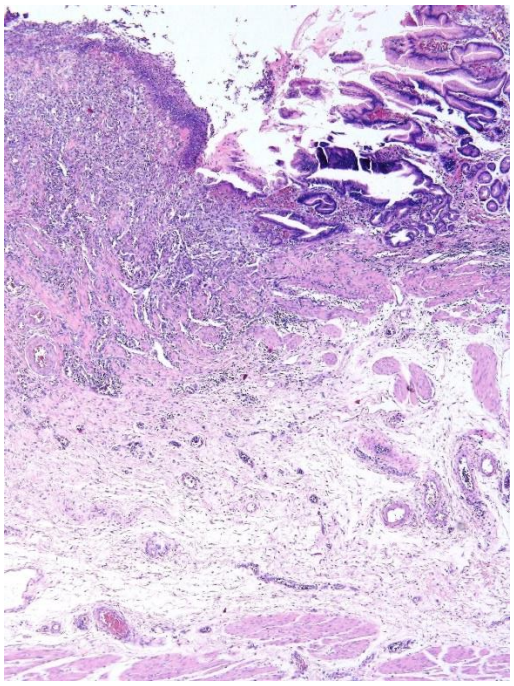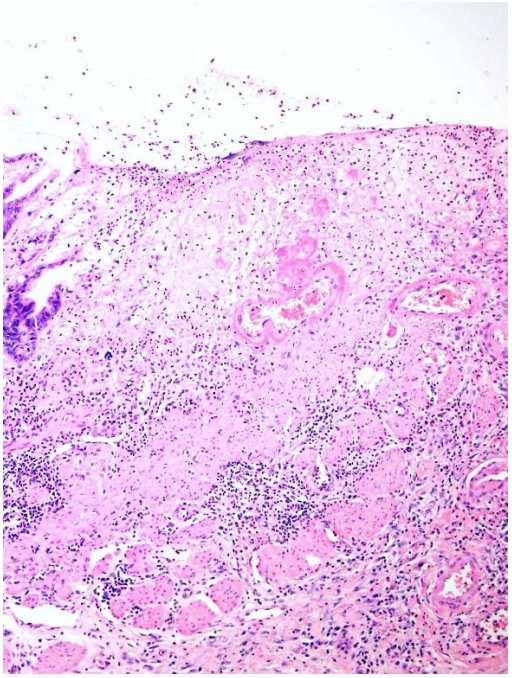
COMMENT: Helicobacter pylori infection is the most common predisposing cause of peptic ulcers.