CODE: T6300 M8013/3

ID NOS: HX224890 27095

DIAGNOSIS: STOMACH - ADENOCARCINOMA

CLINICAL HISTORY: M/60. Whilst under treatment for an exacerbation of eczema, physical examination of this patient disclosed a 10cm mass above the umbilicus. There were no symptoms referable to this, but a barium meal showed a large filling defect in the distal third of the stomach on the greater curvature. At gastrectomy, the mucosa appeared to be normal and the mass was thought to be extrinsic. Gastrectomy was performed.

MACROSCOPIC: The specimen is part of the stomach and contains a tumour 9cm long and 4.5cm wide projecting into the lumen. The thin transverse slice mounted separately shows the growth to be infiltrating through the muscle layer, and the mucosa and submucosa are pale and greatly thickened.
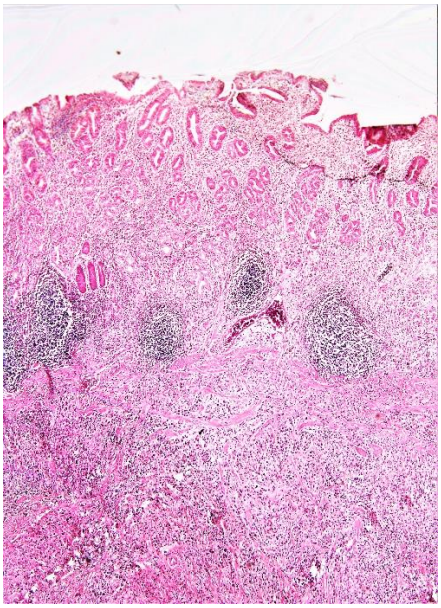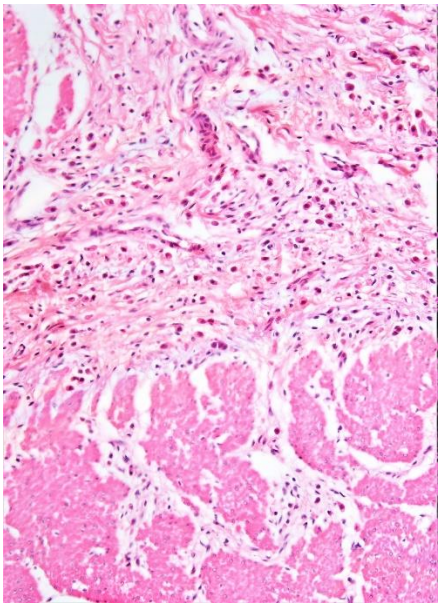
MICROSCOPIC: This is a poorly adenocarcinoma of the stomach. The microscopic examination shows diffuse infiltration of the stomach wall (left image) with tumour cells extending from the submucosa and infiltrating into the muscularis propria fibres (right image).