CODE: T6300 M8220

ID NOS: HX102996 A16466

DIAGNOSIS: STOMACH – MULTIPLE POLYPS, CRONKHITE-CANADA SYNDROME

CLINICAL HISTORY: M/60. This patient presented 12 months before death with intractable diarrhoea and was shown to have multiple polyps in the stomach, duodenum and large bowel. He also had nail atrophy, alopecia and skin pigmentation as described in Cronkhite-Canada syndrome.

MACROSCOPIC: The specimen consists of portion of the stomach wall. Some areas of the mucosa show prominent longitudinal rugae and other areas show polypoid projections varying in size up to 1cm in diameter.

MICROSCOPIC: The sections showed polypoid irregularity of the mucosa with oedema of the lamina propria and cystic dilatation of glands, many of which are lined by flattened epithelium.
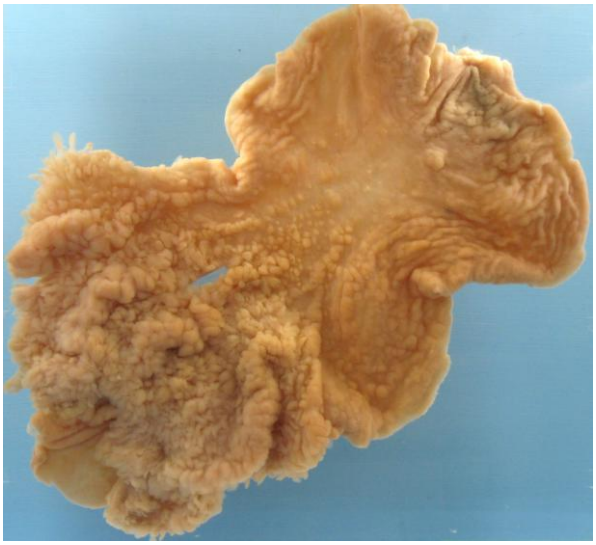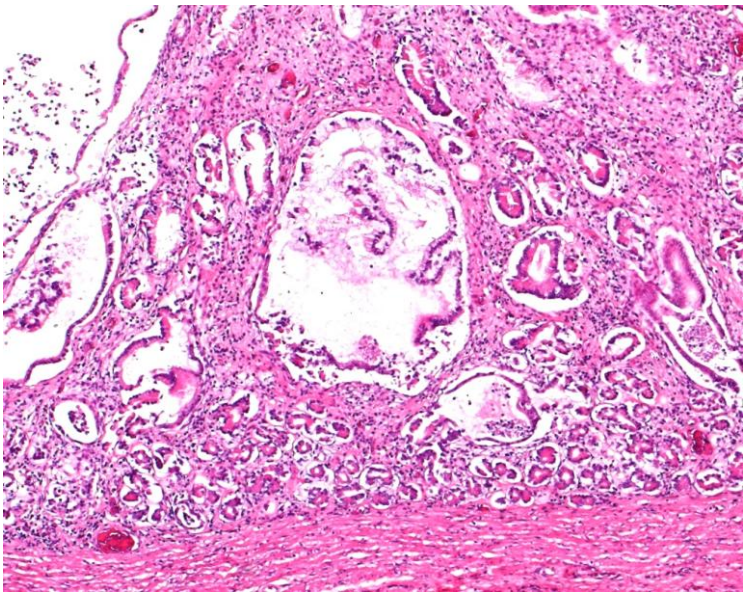
COMMENT: See also specimens of large bowel and finger nail from this patient.