CODE: T6401 M5470

ID NOS: H423390; 146508

DIAGNOSIS: SMALL BOWEL - INFARCTION (STRANGULATION)

CLINICAL HISTORY: F/38. Laparotomy six years previously. Ten hour history of acute abdominal pain and vomiting. At operation, loop of small bowel twisted and strangulated by a fibrous band. Infarcted bowel excised with end-to-end anastomosis.

MACROSCOPIC: Specimen consists of a twisted loop of dark haemorrhagic small bowel. A thick white fibrous band is present at the base of the twisted segment.
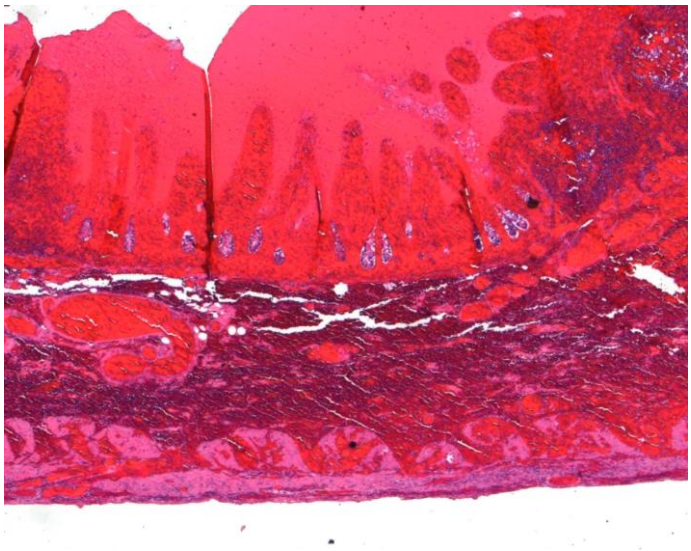
MICROSCOPIC: The sections showed full thickness haemorrhagic infarction of the small bowel.