CODE: T6401 M9120

ID NOS: H397645; A17424

DIAGNOSIS: HAEMANGIOMA OF SMALL INTESTINE.

CLINICAL HISTORY: F/53. Hypertensive cardiovascular disease. Incidental finding at autopsy of multiple small purple coloured sessile polyps throughout the small intestine.

MACROSCOPIC: Portion of small intestine which shows a number of small dark lesions, some of which appear slightly polypoid.
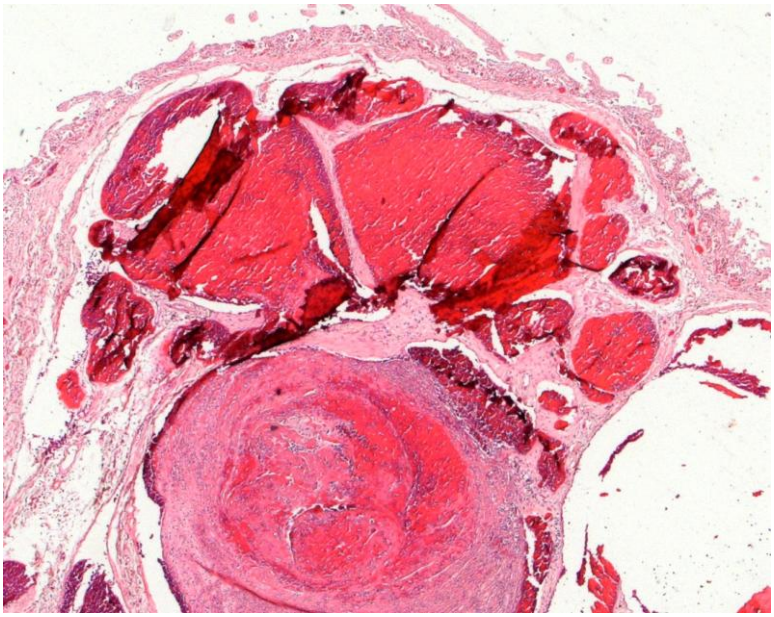
MICROSCOPIC: Sections show numerous dilated vascular spaces within the submucosa of the intestine consistent with haemangiomata. The mucosa is rather autolysed.