CODE: T6500 M4455/4

ID NOS: H382189 112303

DIAGNOSIS: SMALL BOWEL - CROHN'S DISEASE.

CLINICAL HISTORY: F/23. Long history of severe diarrhoea with pain. Three laparotomies performed for obstruction, one with bowel resection.

MACROSCOPIC: Specimen consists of portion of small bowel (terminal ileum) and caecum. In the ileum, near the proximal cut end and also near the ileo-caecal valve there is diffuse thickening of the bowel wall with oedematous and prominent mucosa (cobblestone appearance). Lymphoid tissue is prominent on the serosal surface of these affected areas. Between these two areas the bowel appears normal.
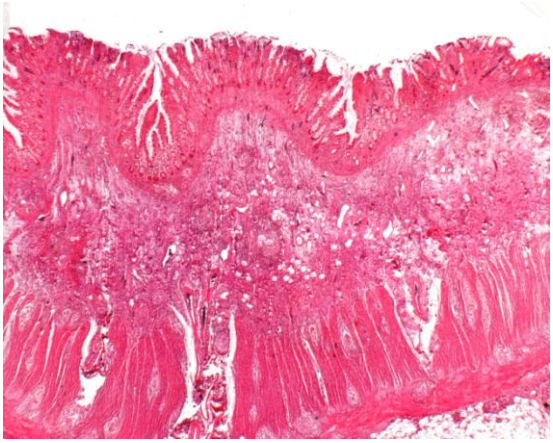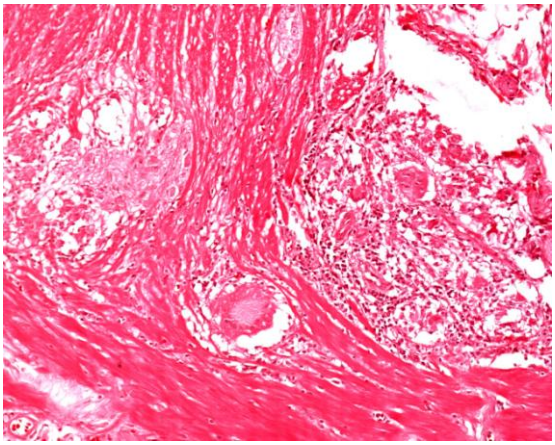
MICROSCOPIC: Sections of the affected ileum show full thickness inflammation (left) with lymphocytic infiltrate and non-caseating granulomas (right) throughout all layers of the bowel wall. The mucosa is ulcerated with oedema of the submucosa. The features are those of Crohn's disease.