CODE: T6510 M8016/2

ID NOS: Lewisham Hospital 1021

DIAGNOSIS: JEJUNUM – METASTATIC CARCINOMA.

CLINICAL HISTORY: F/48. This patient presented with symptoms of subacute intestinal obstruction of two weeks duration. She had previously been diagnosed with carcinoma of the bladder. On admission her haemoglobin was 13.7g% and she was transfused with packed red cells prior to laparotomy. A segment of jejunum with a tumour mass was resected, and an enlarged mesenteric lymph node was also noted..

MACROSCOPIC: The specimen consists of a segment of jejunum with a pale tumour 45mm in diameter which has partially obstructed the lumen.
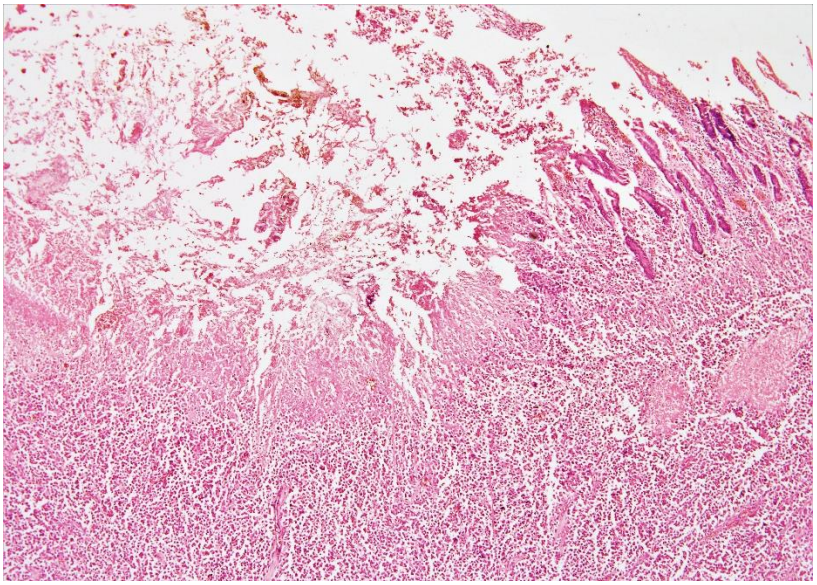
MICROSCOPIC: The section shows the small bowel wall is infiltrated by a poorly differentiated carcinoma with features consistent with metastatic high grade urothelial carcinoma.