CODE: T6600 M3526/1

ID NOS: NS53476; 18870

DIAGNOSIS: MUCOCOELE OF THE APPENDIX.

CLINICAL HISTORY: M/41. This patient was said to have suffered from repeated attacks of lower right sided abdominal pain for three months prior to appendicectomy.

MACROSCOPIC: The appendix is greatly distended by opalescent mucus and the subserosal blood vessels are engorged. The lumen near the resected end is obliterated.
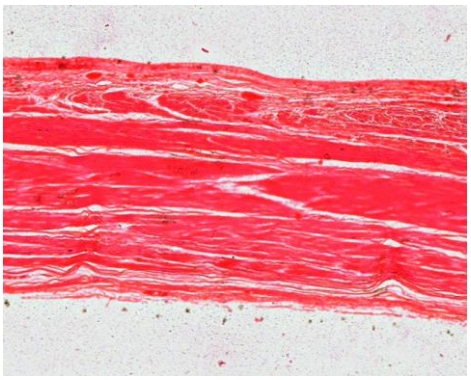
MICROSCOPIC: All traces of mucosa and submucosa have disappeared and the muscularis is replaced by dense collagen.