CODE: T6600 M3526/2

ID NOS: H53747 33724

DIAGNOSIS: APPENDIX - MUCOCELE (LOW GRADE MUCINOUS NEOPLASM)

CLINICAL HISTORY: M/70. This man came to hospital for dilatation of a urethral stricture. Physical examination detected a painless lump in the right iliac fossa. Laparoscopy was performed for a suspected cancer of the caecum.

MACROSCOPIC: This diaphanous sac represents the appendix which had become distended with mucus. There was no communication between the lumen of the appendix and caecum. The specimen originally measured 70x50x40mm and contained yellow mucoid material.
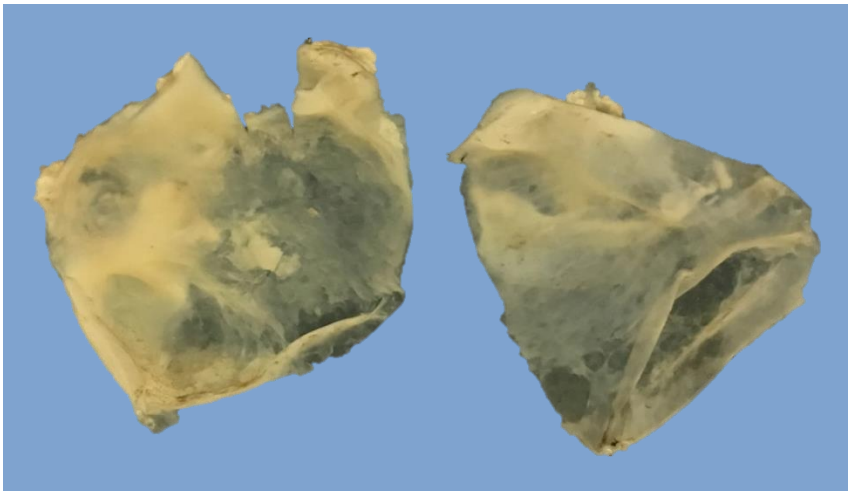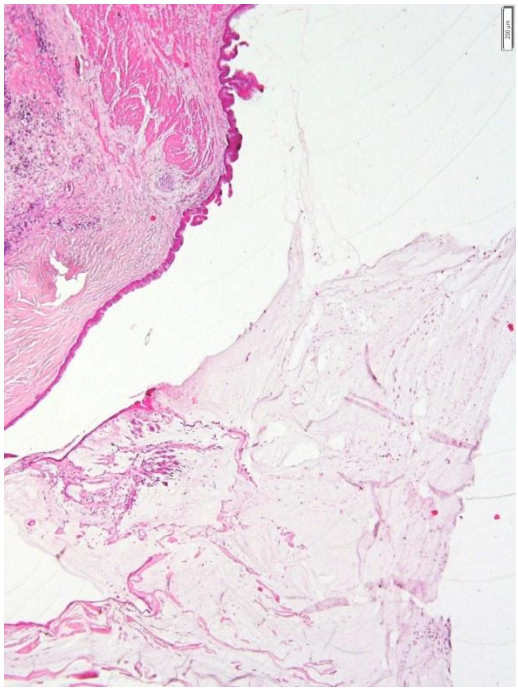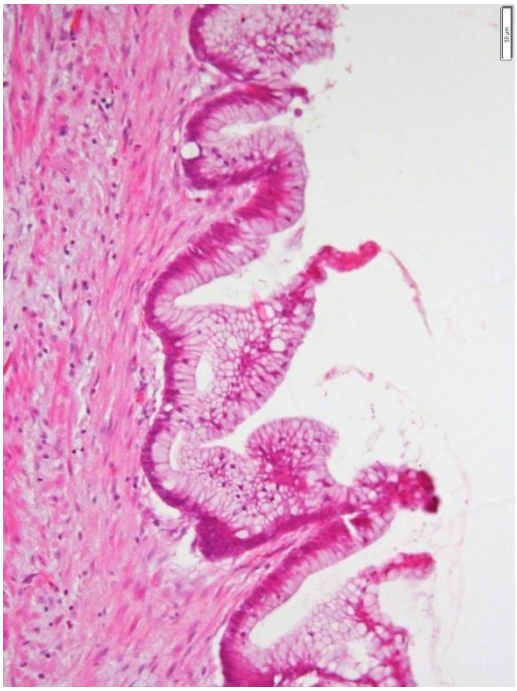
MICROSCOPIC: The cyst is lined by uniform columnar epithelium and mucus can be seen to overlie the mucosal surface (left image). The epithelium is mucinous with some papillary tufting (right image).