CODE: T6700 M4455/2

ID NOS: H327457 97646

DIAGNOSIS: COLON – CROHNS DISEASE

CLINICAL HISTORY: F/55. This patient gave a history of watery diarrhoea with some mucus but no blood for about 18 months, with more recent loss of weight and lower abdominal pain. Sigmoidoscopy showed acute colitis with deep ulcerations. A total colectomy was performed and she was left with an ileostomy. She was well when seen a year later. Her daughter was also known to have Crohns disease.

MACROSCOPIC: The terminal ileum and the ileo-caecal valve are at he bottom of the specimen. The colon is universally congested and oedematous and criss-crossed by deep linear ulcers leading to a cobblestone appearance. The serosal surface is also congested.
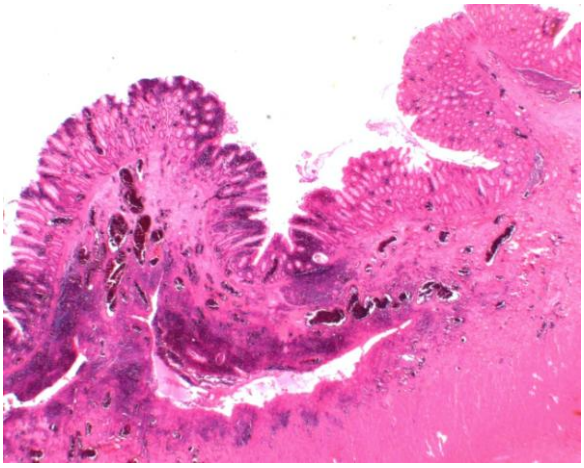
MICROSCOPIC: The section shows an ulcer undermining the adjacent mucosa. Other ulcers formed deep fissures extending into the muscle layer. There is surrounding nonspecific chronic inflammation which also involves the muscularis. Although not diagnostic, the changes support the diagnosis of Crohns disease.