CODE: T6700 M4455/3

ID NOS: H32243 89919

DIAGNOSIS: COLON - RECURRENT CROHN'S DISEASE

CLINICAL HISTORY: F/39. The diagnosis of Crohn's disease was first made in 1992 when right hemi-colectomy was performed. Seven years later bouts of diarrhoea and colic reappeared together with some vomiting. As it was thought that the disease had recurred at the site of the previous anastomosis, laparotomy was undertaken and a further resection was performed. The patient was well two years later.

MACROSCOPIC: In the middle third of the specimen, a stricture represents the site of the original anastomosis above which are irregular pale sloughs indicating recurrence of the original disease (left image). The small intestine above is both hypertrophied and dilated. Large intestine is below the stricture.
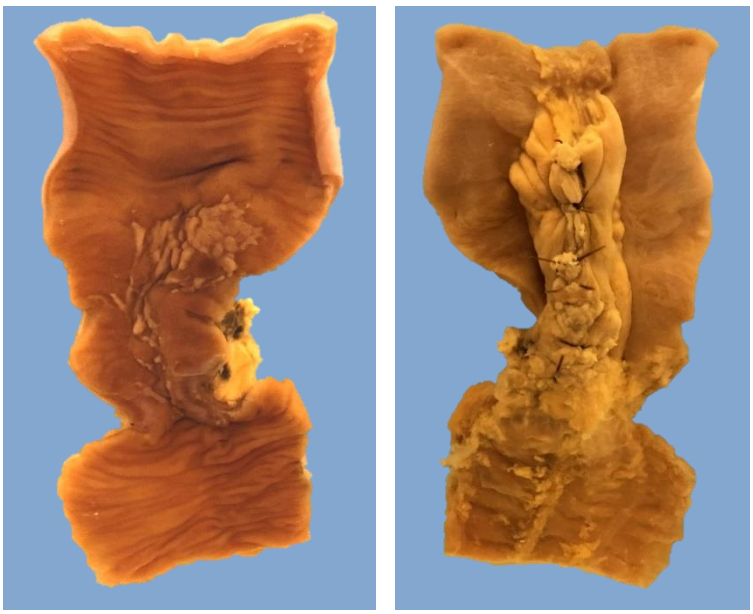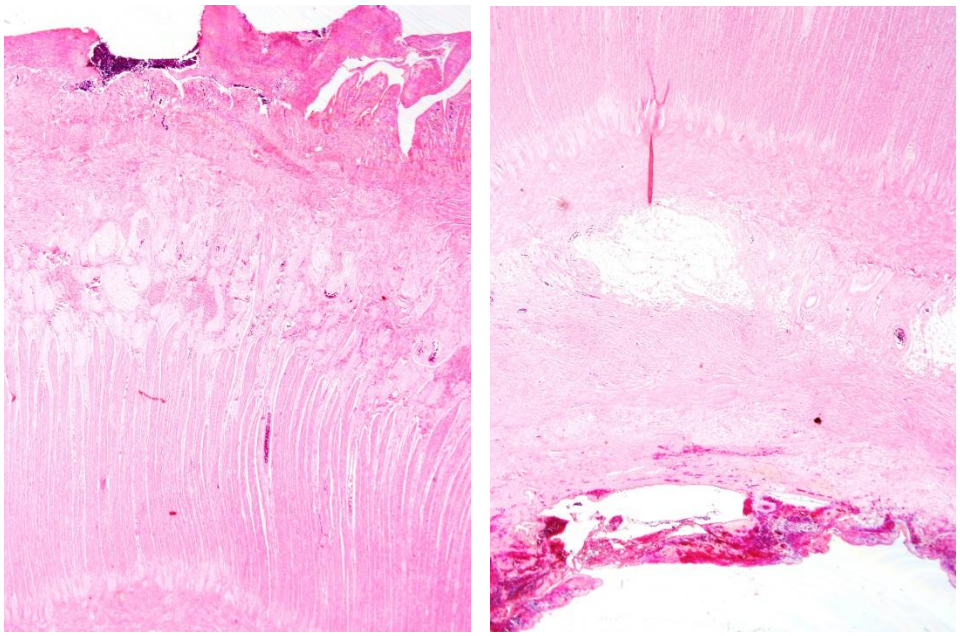
MICROSCOPIC: There is mucosal ulceration, fibrosis of the submucosa and lymphocytic aggregates (left image). The serosal surface is haemorrhage and there is fibrosis of the subserosa (right image).