CODE: T6700 M4641/4 & M4631
T5700 M3100

ID NOS: 764042 AB137650

DIAGNOSIS: RIGHT COLON - CHOLECYSTOCOLIC FISTULA
LEFT COLON – DIVERTICULAR STRICTURE + IMPACTED GALL STONE

CLINICAL HISTORY: F/76. The patient had biliary sepsis due to a cholecystocolic fistula, and presented with large bowel obstruction due to gall stone impaction in a diverticular stricture. A right hemicolectomy with removal of the adherent gall bladder and fistula was performed, as well as a segment of sigmoid colon, which includes an impacted gall stone at the site of a diverticular stricture.

MACROSCOPIC: The specimen consists of two segments of colon. The right hemicolectomy includes 42mm of terminal ileum with 200mm of caecum and ascending colon. The fistula tract (arrow) which had been connected to the gall bladder is close to the distal margin. The segment of sigmoid colon shows diverticular disease with a gall stone 40x35x30mm impacted above a stricture at the lower end.
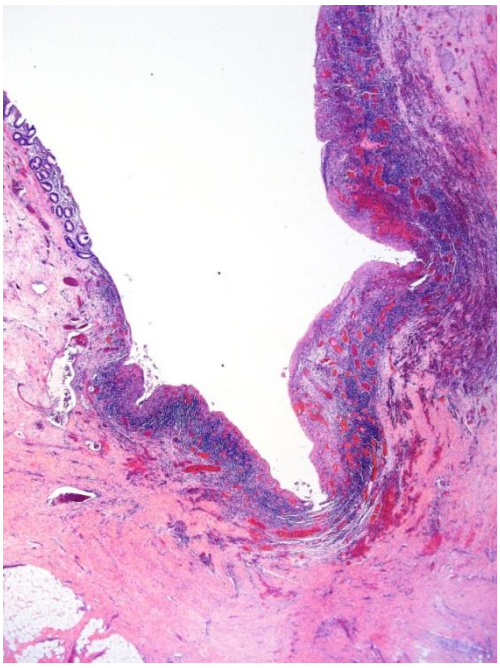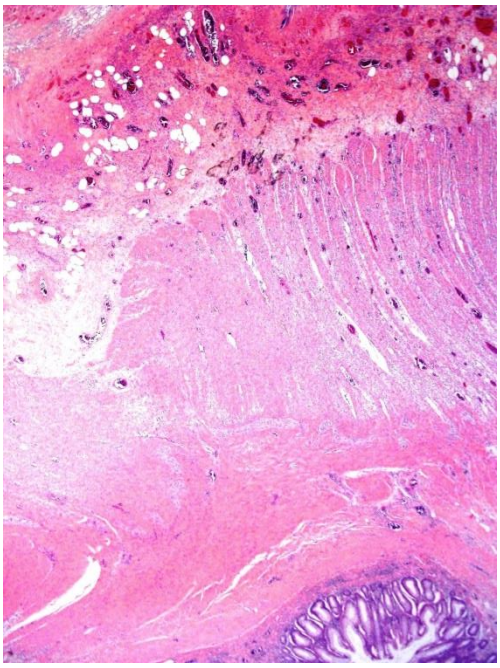
MICROSCOPIC: Section of the fistula tract (left image) shows a lining of granulation tissue infiltrated by acute and chronic inflammatory cells, with colonic mucosa ate the left. Section of the stricture (right image) shows granulation tissue overlying the hypertrophied muscle layer, with part of a diverticulum deep to the muscle.