CODE: T6700 M5407/1

ID NOS: H40857 A11386

DIAGNOSIS: COLON - ISCHAEMIC COLITIS.

CLINICAL HISTORY: M/74. The patient was admitted to hospital because of a painful cold right foot which was later shown to result from common iliac arterial thrombosis. Whilst in hospital he became hypotensive and died of bronchopneumonia.

MACROSCOPIC: This segment of colon shows normal rugose mucosa alternating with smooth areas resulting from recent ulceration. The autopsy report noted that there was severe atherosclerosis in the aorta, the coronary arteries and the iliac arteries; it is likely that the mesenteric vessels were similarly involved. This with the hypotension, would explain the ischaemic colitis.
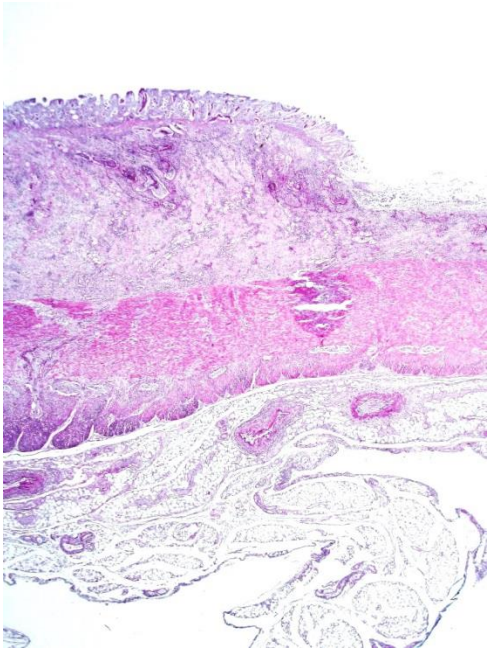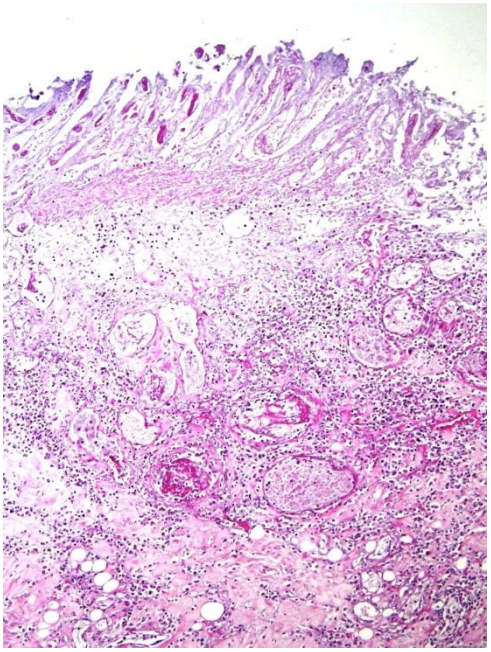
MICROSCOPIC: The intestinal wall is partially necrotic and patchily ulcerated (left image). Neutrophils are numerous in the mucosa and submucosa, with blood vessels contain recent fibrin thrombi (right image). The changes are those of ischaemic colitis.