CODE: T6700 M5407/2

ID NOS: HX142317; 123288

DIAGNOSIS: ISCHAEMIC COLITIS.

CLINICAL HISTORY: M/71. Generalised atherosclerosis (abdominal aneurysm grafted, carotid endarterectomy, myocardial infarct). Two day history of lower abdominal pain and bloating diarrhoea. Laparotomy with hemicolectomy performed. Patient subsequently died.

MACROSCOPIC: Specimen consists of portion of colon in the middle third of which is a fairly well demarcated area of mucosal ulceration covered by greenish slough.
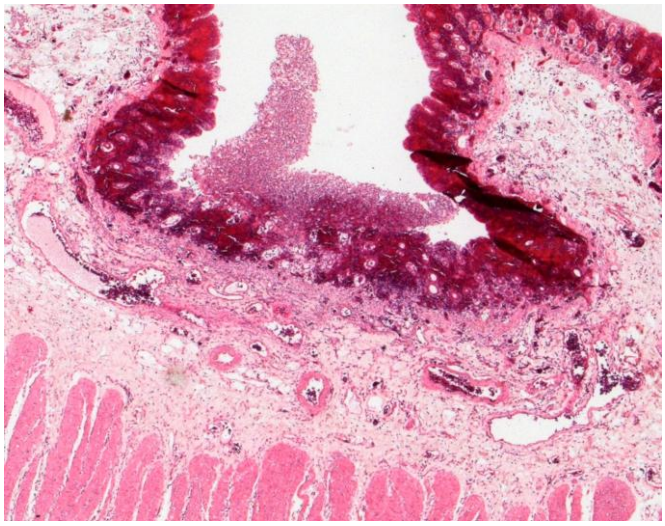
MICROSCOPIC: Sections of the ulcer show necrosis of the mucosa with a mixed inflammatory cell infiltrate. Some small submucosal vessels contain fibrin thrombi and larger vessels contain atheromatous emboli.