CODE: T6700 M8143/6

ID NOS: HB114542 96554

DIAGNOSIS: TRANSVERSE COLON – ADENOCARCINOMA

CLINICAL HISTORY: F/84. This patient complained of marked and rapid weight loss accompanied by anorexia and nausea, with episodes of diarrhoea. A firm mass was palpable in the umbilical region. Transverse colectomy was performed followed by cobalt therapy, but death ensued a year later.

MACROSCOPIC: There is an elongated fungating tumour encircling the colon, and extending through the muscle layer. No lymph nodes were involved.
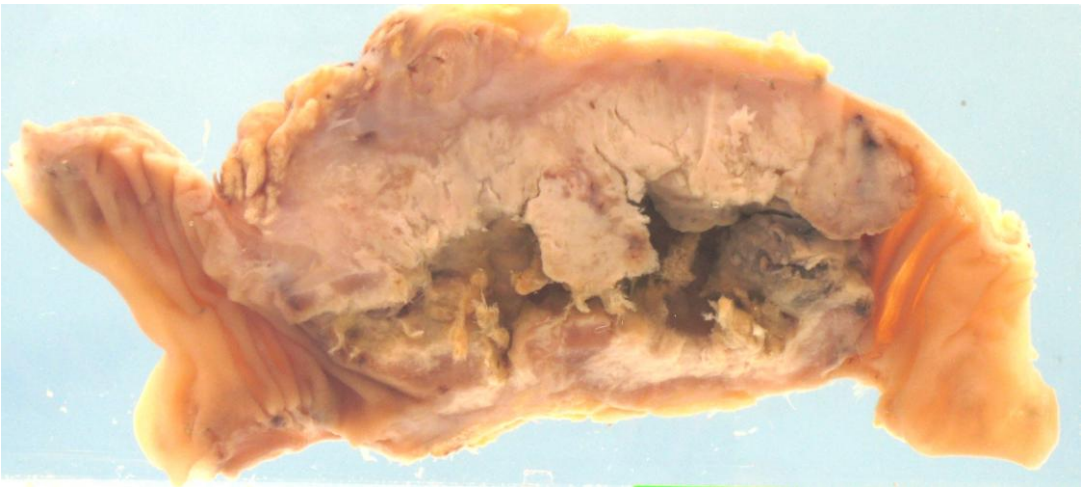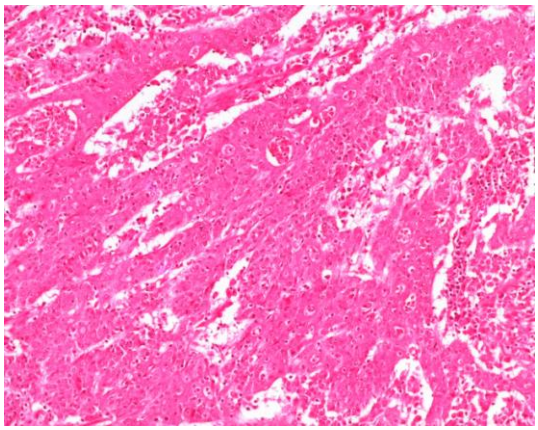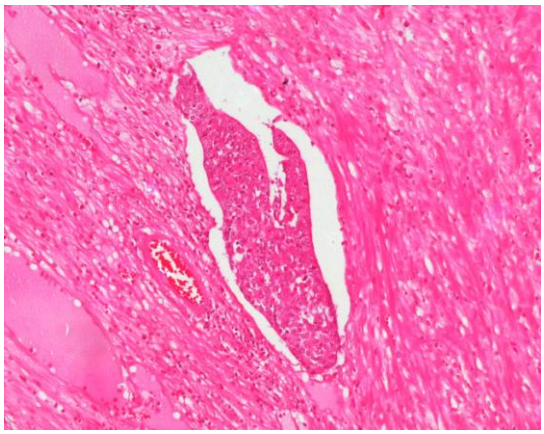
MICROSCOPIC: The sections of the tumour show poorly differentiated adenocarcinoma (left image). Venous invasion is present (right image).