CODE: T6700 M8850/2

ID NOS: HX30301 98940

DIAGNOSIS: COLON – SUBMUCOSAL LIPOMA

CLINICAL HISTORY: M/66. The patient presented to Casualty with a two week history of melaena and increasing anaemia. Gastroscopy and sigmoidoscopy revealed nothing abnormal, but a barium enema demonstrated a polypoid filling defect at the hepatic flexure. A right hemicolectomy was performed.

MACROSCOPIC: There is a rounded polyp 2cm diameter protruding into the lumen of a segment of otherwise normal looking colon.
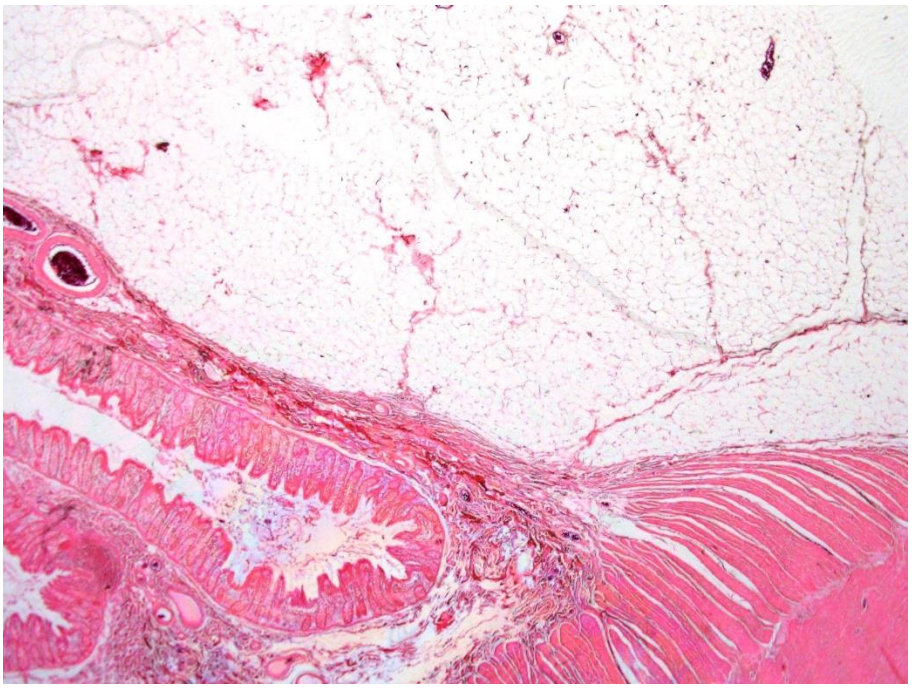
MICROSCOPIC: The section shows normal looking adipose tissue between the mucosa and the muscle coat, confirming the diagnosis of a submucosal lipoma.