CODE: T6700 M8850/3 M5711/2

ID NOS: HX245636 124387

DIAGNOSIS: COLON – SUBMUCOSAL LIPOMA, MELANOSIS COLI

CLINICAL HISTORY: M/78. The patient complained of increasing constipation for which he took laxatives. Barium enema and colonoscopy showed a polypoid lesion in the descending colon which was removed by local resection and end to end anastomosis.

MACROSCOPIC: The specimen consists of portion of a sessile tumour attached to a piece of colonic mucosa. The cut surface of the tumour has a yellow colour. The mucosa shows the dark pigmentation of melanosis coli.
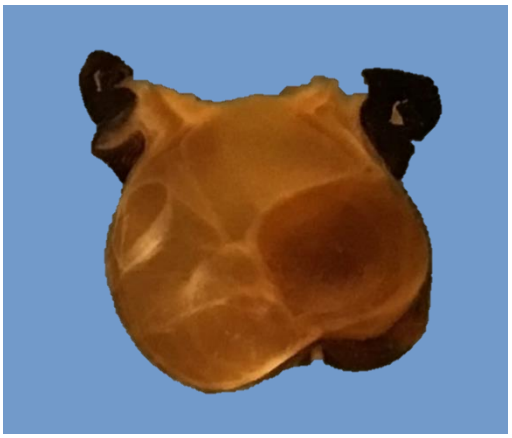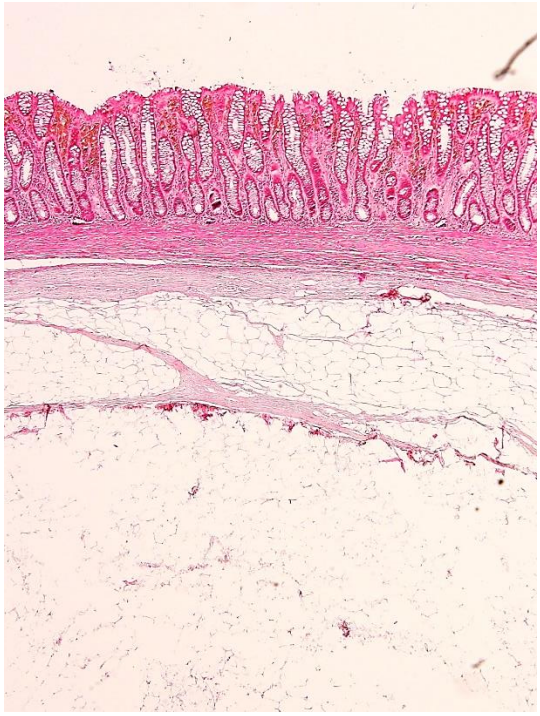
MICROSCOPIC: The section of the tumour shows mature adipose tissue typical of a lipoma (left image). The mucosa contains brownish lipofuscin pigment within macrophages (right image).