CODE: T6710 M9540

ID NOS: HX41832 134217

DIAGNOSIS: ILEO-CAECAL REGION – MYXOID NEUROFIBROMA

CLINICAL HISTORY: M/65. The patient presented with right sided lower abdominal pain and a palpable mass. Two years previously, right nephrectomy was performed for renal cell carcinoma. At operation, a tumour in the ileo-caecal region was excised. There was no evidence of recurrent renal cell carcinoma seen at operation.

MACROSCOPIC: The specimen consists of portion of terminal ileum, caecum and ascending colon. A 12cm mass attached to the serosal surface of the bowel wall has been bisected. The cut surface shows a pale, circumscribed tumour with an area of cystic degeneration along one margin.
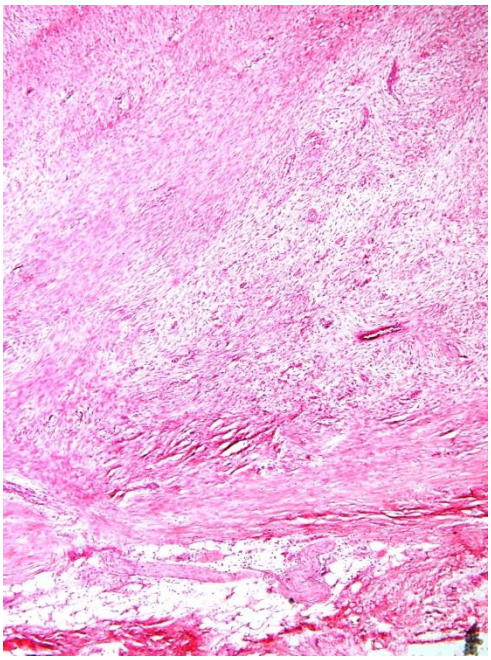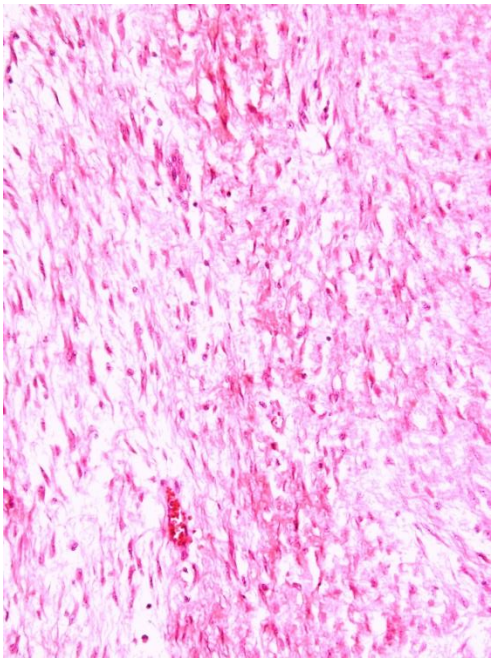
MICROSCOPIC: The sections show an encapsulated tumour with pale myxoid areas (left image). The tumour is composed of spindle cells (right image) with mild nuclear atypia. There was positive staining for S100 protein demonstrated, supporting the diagnosis of a myxoid neurofibroma.