CODE: T6800 M8143/4

ID NOS: 267

DIAGNOSIS: RECTUM – ADENOCARCINOMA

CLINICAL HISTORY: M/60. Abdomino-perineal resection was performed for low carcinoma of the rectum.

MACROSCOPIC: The specimen includes distal sigmoid, rectum, anal canal and perianal skin. There is an ulcerated tumour 40mm in length which abuts the ano-rectal margin, and has infiltrated to the deep resection margin
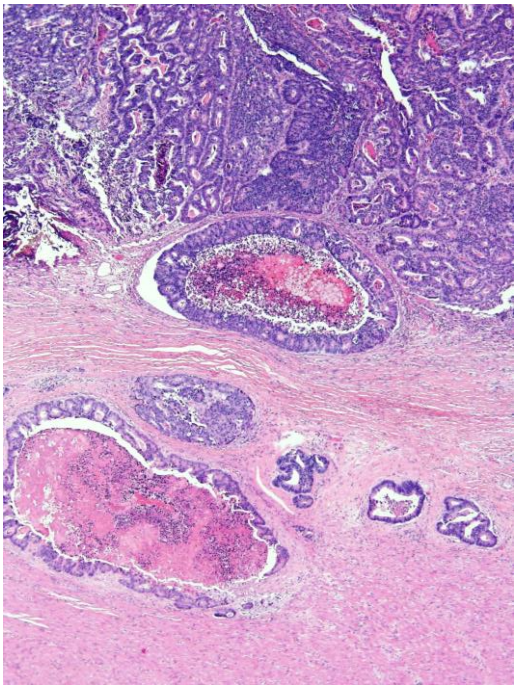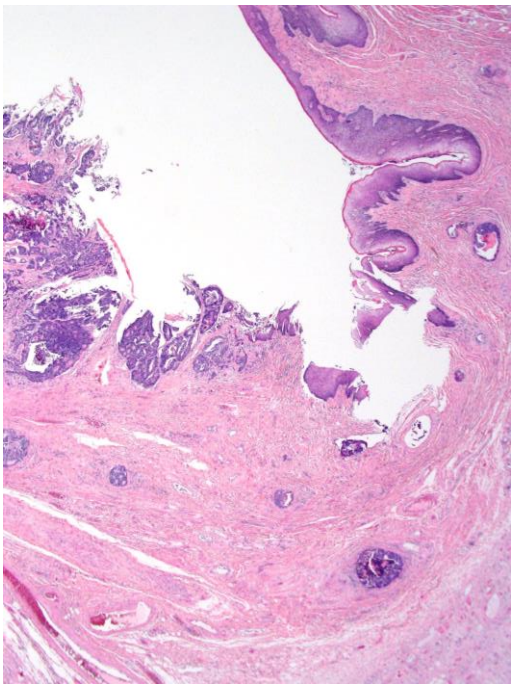
MICROSCOPIC: The sections moderately differentiated adenocarcinoma, with tumour necrosis, infiltrating into the muscle layer (left image). The tumour also extends beneath the anal mucosa (right image).