CODE: T6800 M8210/2

ID NOS: H38227 17656

DIAGNOSIS: RECTUM – TUBULOVILLOUS ADENOMA

CLINICAL HISTORY: M/66. The patient gave a three year history of intermittent diarrhoea with passage of excessive mucus. Resection with end-to-end anastomosis was performed.

MACROSCOPIC: The specimen of rectum measures 20cm in length. The lower third of the specimen is encircled by a folded papillomatous mass. Three smaller polyps are present on the mucosal surface. There is no obvious ulceration of the mucosal surface.
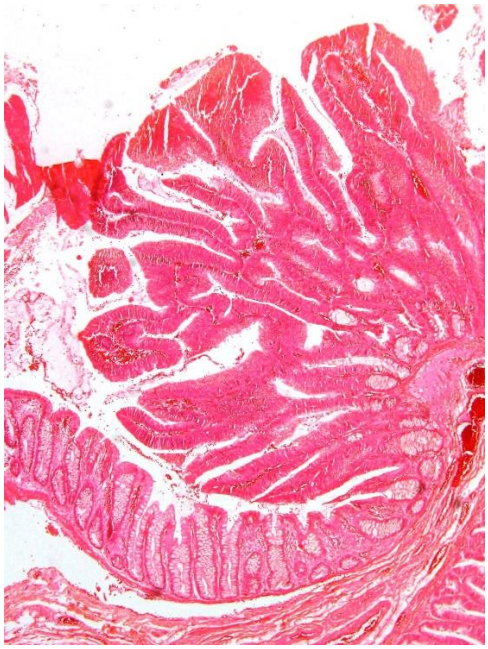
MICROSCOPIC: The tumour is a tubulovillous adenoma with a prominent villous component. There is low grade dysplasia, but no evidence of high grade dysplasia or invasion.