CODE: T6800 M8260

ID NOS: 131164

DIAGNOSIS: RECTUM – TUBULOVILLOUS ADENOMA

CLINICAL HISTORY: M/51. The patient presented with rectal bleeding. Local excision of a rectal tumour was performed.

MACROSCOPIC: The specimen of mucosal tissue is almost completely covered by polypoid excrescences. Some lesions are smooth and rounded, while others show a shaggy villous appearance.
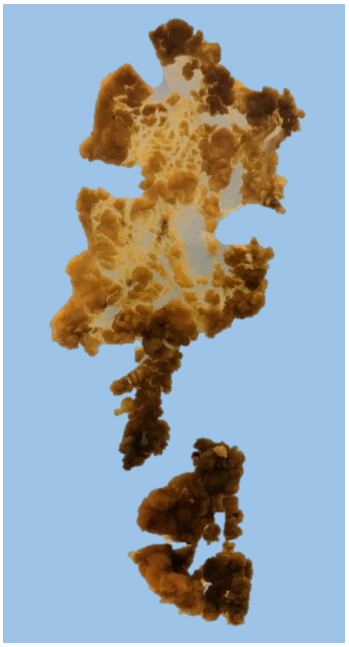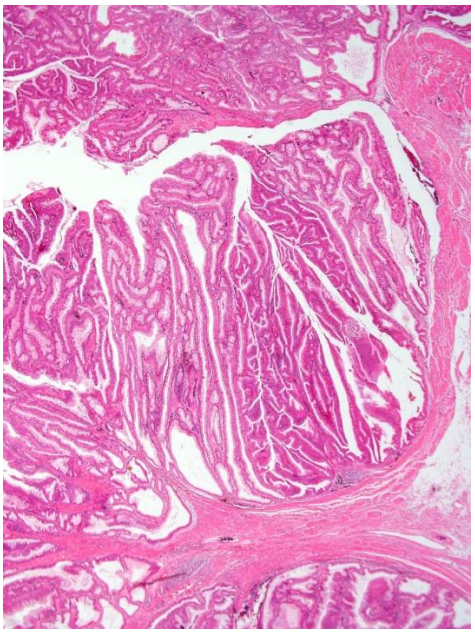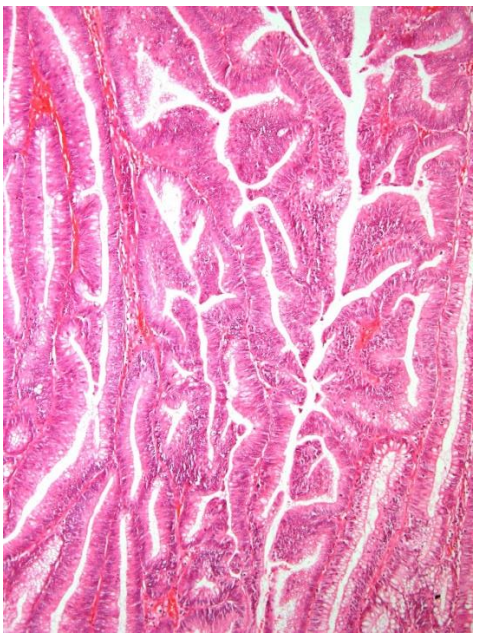
MICROSCOPIC: The tumour is a tubulovillous adenoma with a mixture of finger-like and broad processes (left image). There is low grade dysplasia (right image), but no evidence of high grade dysplasia or invasion.