CODE: TY410 M9151/1

ID NOS: 7671 54396

DIAGNOSIS: OMENTUM – SOLITARY FIBROUS TUMOUR

CLINICAL HISTORY: Following vague abdominal discomfort, an intra-abdominal lump was detected, just above the right iliac fossa. Laparotomy showed a mass in the greater omentum, which was removed.

MACROSCOPIC: A portion of the omentum is still attached to a well defined pear shaped mass. The cut surface reveals pale tan tissue with a number of thin walled cysts and a solitary chalky white area.
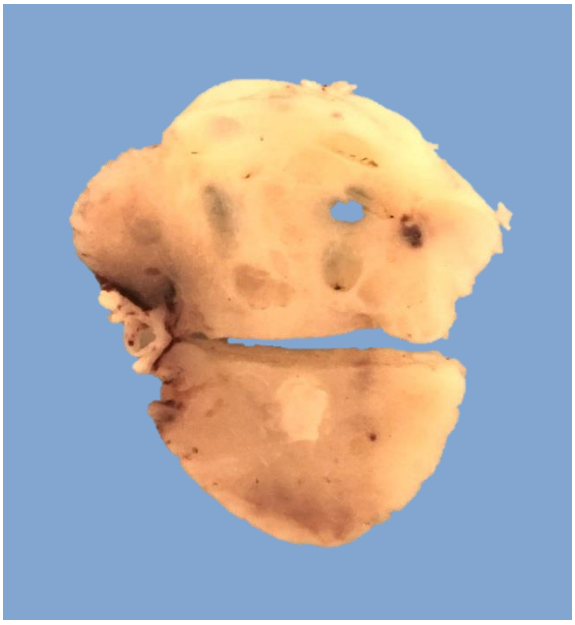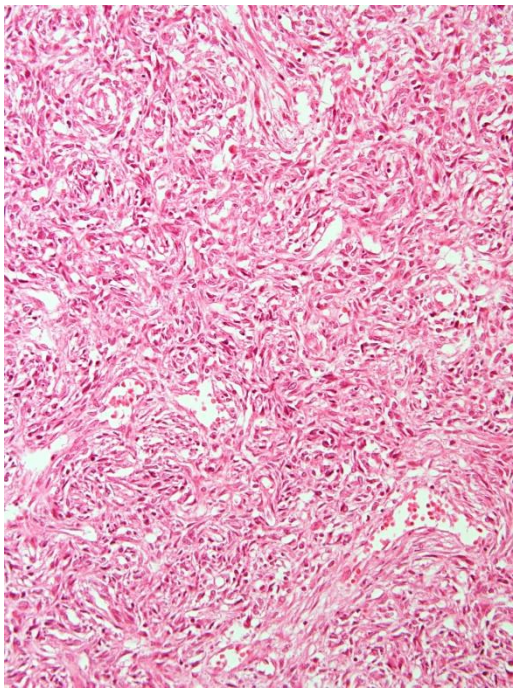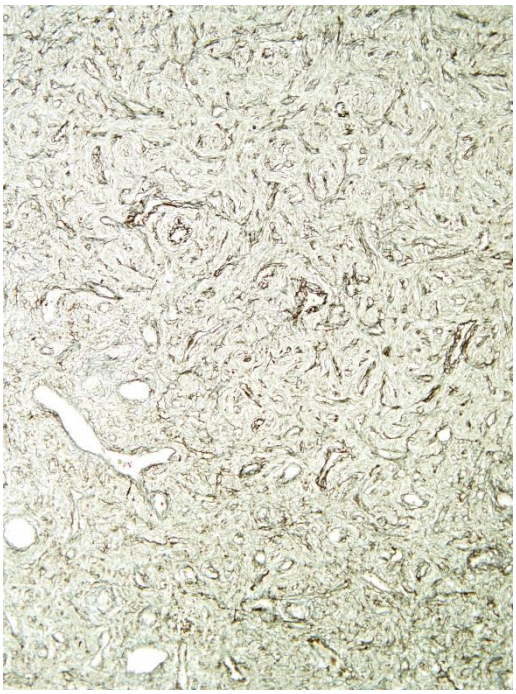
MICROSCOPIC: The tumour shows variable cellularity. The more cellular areas showing plump spindle cells with numerous branching thin walled blood vessels (left image). The pattern of the vasculature becomes more obvious with the reticulin stain (right image). This tumour was previously called a haemangiopericytoma.