CODE: T0700 F9107/1

ID NOS: 2/8051 10540

DIAGNOSIS: SPLEEN – FAMILIAL ANAEMIA – HEREDITARY SPHEROCYTOSIS.

CLINICAL HISTORY: M/24. The patient presented with pallor and jaundice and the spleen was found to be enlarged. Haemoglobin was reduced to 9g/100ml, reticulocytes were 35% and osmotic fragility of the red blood cells was increased. Splenectomy was performed. The mother had her spleen removed following splenic rupture and she also had reticulocytosis and increased osmotic fragility.

MACROSCOPIC: The spleen is several times larger than normal and is dark reddish brown in colour.
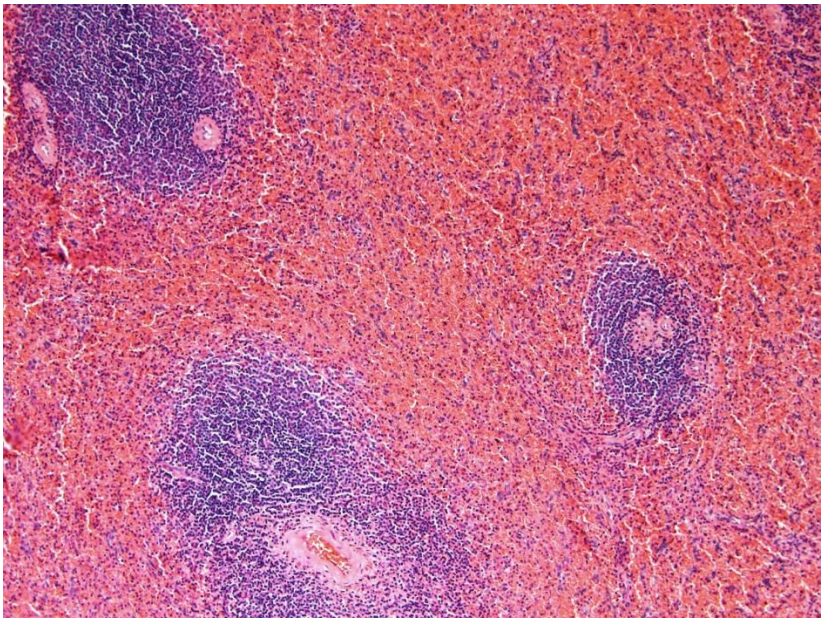
MICROSCOPIC: Sections show that the Malpighian corpuscles are widely separated by congested red pulp. The picture is non- specific.