CODE: T0700 M8006/1

ID NOS: NX15146 A6090

DIAGNOSIS: SPLEEN - METASTATIC MALIGNANT MELANOMA

CLINICAL HISTORY: M/45. Four years before death, a malignant melanoma was removed from the skin of the groin. The patient died from cerebral metastases. Other metastases were wide spread, however the liver was not involved.

MACROSCOPIC: The spleen is of normal size and contains a single rounded nodule in the centre of the specimen.
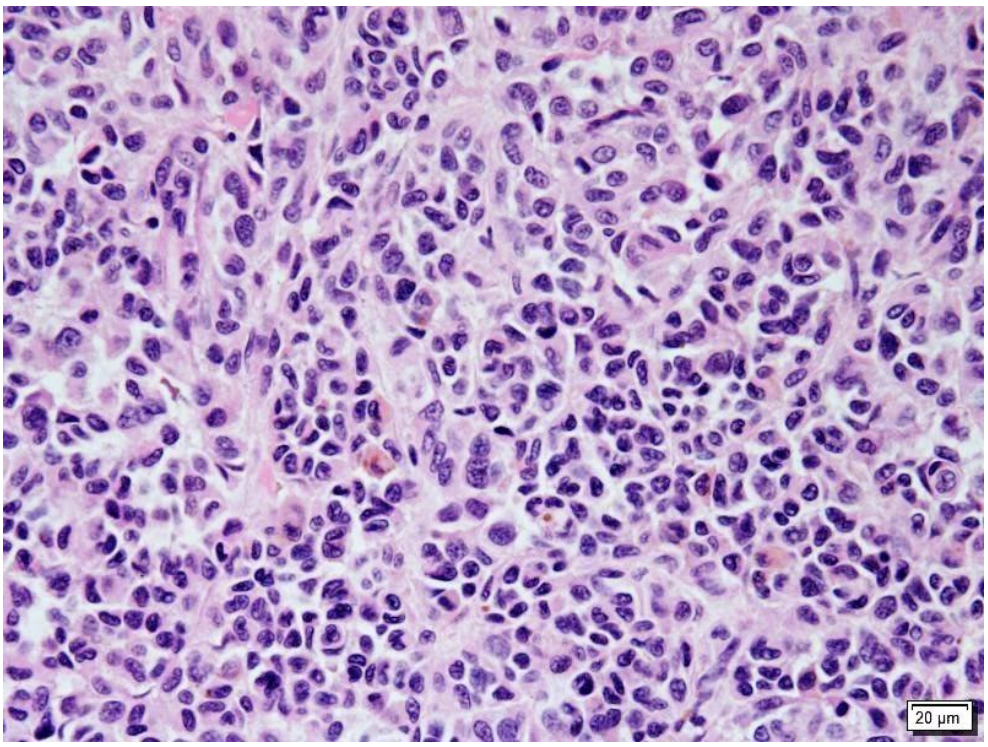
MICROSCOPIC: The tumour consists of sheets of undifferentiated malignant cells with scanty brown pigment.