**CODE:** T0700 M9653/2

**ID NOS:** HX159848 66897

**DIAGNOSIS:** SPLEEN - HODGKIN'S LYMPHOMA

**CLINICAL HISTORY:** M/57. In 1976, Hodgkin's disease was diagnosed and splenectomy performed at which time abdominal lymph nodes were found to be involved (stage IV). Repeated courses of combined therapy and blood transfusions were administered with some temporary benefit. He finally developed a leukaemic blood picture and died in 1979.

**MACROSCOPIC:** This specimen presents the "German sausage" or hard bake" (American for almond toffee) picture typical of Hodgkin's disease of the spleen. Pale hilar lymph nodes are also involved.
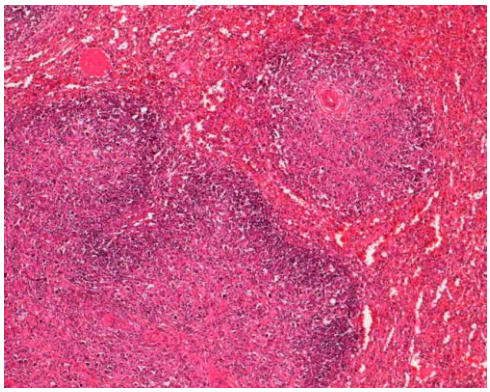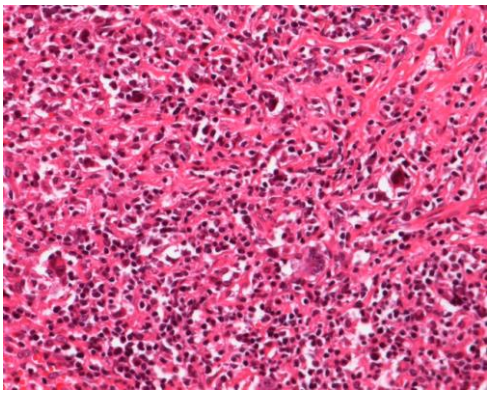
**MICROSCOPIC:** There are nodular foci of pleomorphic cellular infiltration typical of Hodgkin's disease (left). There is some early fibrosis and in some areas, multinucleated Sternberg-Reed cells are prominent in a background of lymphocytes (right).