CODE: T0700 M9703/1

ID NOS: HX87281 A15299

DIAGNOSIS: SPLEEN AND LIVER - MALIGNANT LYMPHOMA (MYCOSIS FUNGOIDES): SPLENIC INFARCT.

CLINICAL HISTORY: M/69. Six months before death, this patient developed increasing scaly erythroderma and a fever. Liver and skin biopsies showed infiltration with malignant lymphoma. He died in spite of intensive combined therapy.

MACROSCOPIC: The spleen (1080g) and liver were both enlarged. There is a large pale splenic infarct seen in an otherwise structureless dark pink cut surface. The lobular structure of the liver is greatly accentuated by pale periportal infiltration by malignant cells.
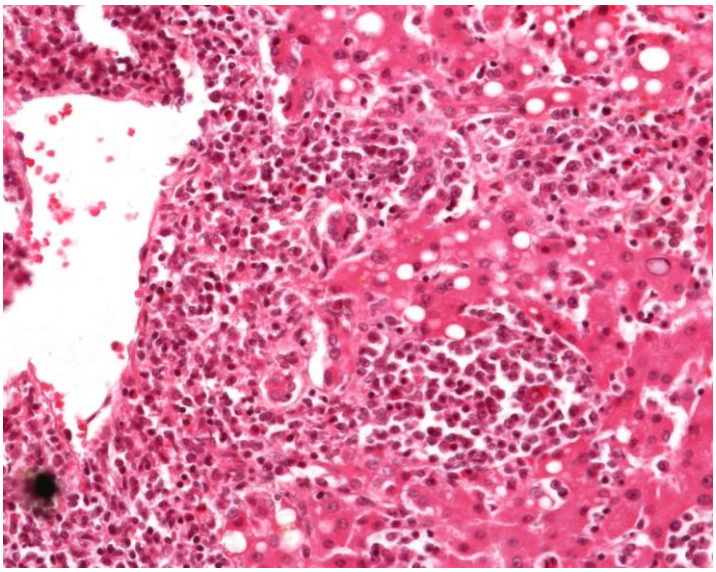
MICROSCOPIC: The portal tracts and sinusoids in the liver are infiltrated by large malignant lymphoma cells.