CODE: T08000 M95903 / T64000 M95903

ID NOS: 172820

DIAGNOSIS: SMALL BOWEL – MALIGNANT LYMPHOMA (B-CELL)

CLINICAL HISTORY: F/76. The patient had a history of previous small bowel obstruction which settled, then severe constipation. At laparotomy, a mass involving the small bowel mesentery was removed, together with a segment of small bowel.

MACROSCOPIC: There is a fleshy mass of enlarge lymph nodes in the small bowel mesentery which originally measured 85x60x30mm. There was focal slight thickening of the mucosal folds also noted.
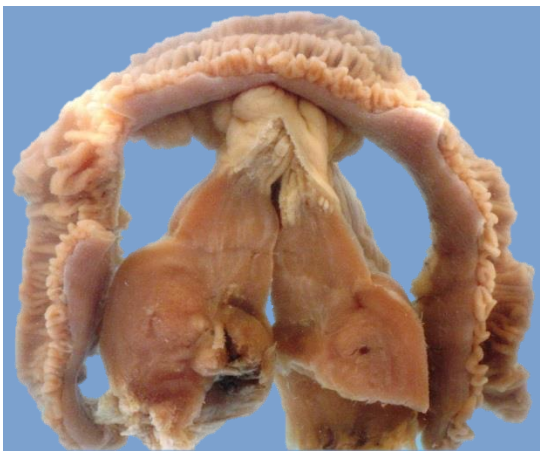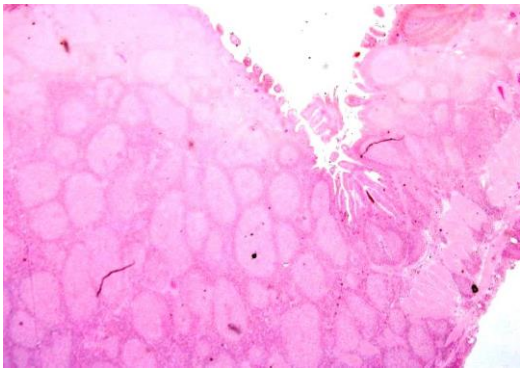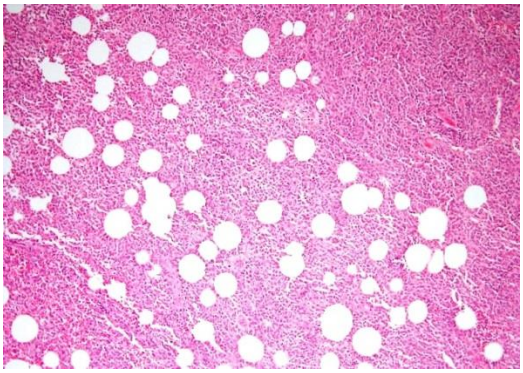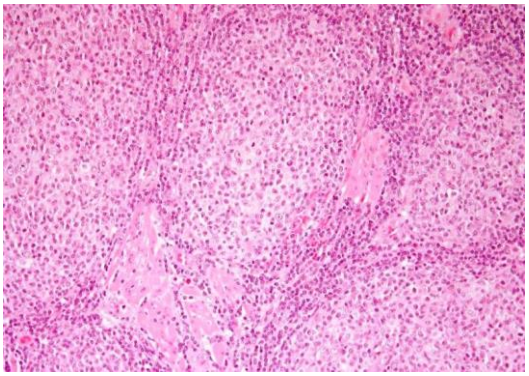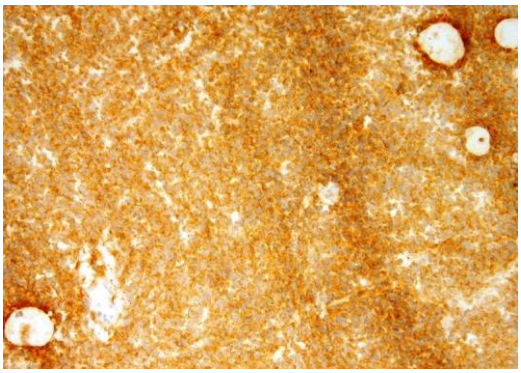
MICROSCOPIC: The small bowel wall has an infiltrate of atypical lymphoid cells which show a follicular pattern (middle left image) and infiltrates into the adjacent fat (middle right image). The lymph node mass has a similar appearance (lower left image). The lymphoma cells stain with CD20, a B-cell marker, supporting the diagnosis of follicular B-cell lymphoma.